

## INTRAOCCULAR FOREIGN BODY: A CASE SERIES

Mega Wulan Purnama Sari<sup>1</sup>, Iwan Sovani<sup>2</sup>, Arief Sjamsulaksan Kartasasmita<sup>2</sup>, Erwin Iskandar<sup>2</sup>, Rova Virgana<sup>2</sup>, Grimaldi Ihsan<sup>2</sup>

<sup>1</sup> Ophthalmology Department Universitas Padjadjaran – Cicendo Eye Hospital, National Eye Center

<sup>2</sup> Vitreoretina Unit, Cicendo Eye Hospital, National Eye Center

### ABSTRACT

**Introduction:** The incidence of Intraocular Foreign Body (IOFBs) among open-globe injuries ranges from 18% to 41%. In addition to clinical examination at the slit-lamp and indirect ophthalmoscopy, various imaging modalities are valuable for the identification and localization of IOFB. Vision loss can be devastating as a result of endophthalmitis, retinal detachment or proliferative vitreoretinopathy (PVR). Timely and appropriate management often leads to favorable anatomic outcomes with restoration of good visual function in the majority of cases. This case report presents the clinical and diagnostic finding, management, outcomes and further plan of the patients with posterior segment IOFB.

**Purpose:** To report some cases of posterior segment intraocular foreign body.

**Case report:** Three patients with history of ocular trauma of the right eye that happened at workplace. All of patients were men in age range 20-55 years old. There were also loss of vision, pain, redness, and from ophthalmological examinations revealed two scleral injuries and one corneal injury that suggest an IOFB in posterior segment. Two patients were suggest endophthalmitis before operation. The plain x ray film examination showed intraocular foreign body in the right eyes. The Ultrasonography (USG) examination also showed intraocular foreign body in the right eyes. All of patient were underwent pars plana vitrectomy. Durante operation 2 of 3 patients were succeed to extract IOFB from the posterior segment, while one patient was not.

**Conclusion:** Preoperative, intraoperative and postoperative management should be done correctly for some cases of IOFB. Prompt treatment and full assessment of patients is important to provide good prognosis.

**Keywords:** Intraocular Foreign Body, Ocular Trauma, Open Globe Injury, Posterior Segment

**Cite This Article:** PURNAMA SARI, Mega Wulan. Intraocular Foreign Fody : A case Series. International Journal of Retina, [S.l.], v. 2, n. 1, aug. 2018. ISSN 2614-8536. Available at: <<https://www.ijretina.com/index.php/ijretina/article/view/38>>.

### INTRODUCTION

The incidence of Intraocular Foreign Body (IOFBs) among open-globe injuries ranges from 18% to 41%. Young men constitute 92%-100% of the patients presenting with IOFBs. The average age of a patient with an IOFB is 29 to 38 years with a majority (66%) betw OFBs among open-globe injuries ranges from 18% to 41%. Young men constitute 92%-100% of the patients presenting with IOFBs. The average age of a patient with an IOFB is 29 to 38 years with a majority (66%) between 21 and 40. The most common place of injury is work (54%-72%) followed by home (30%). Most post-traumatic IOFBs (58%-88%) reside in the

posterior segment.<sup>1-4</sup>

Prompt and full assessment of patients with possible IOFB based on the early signs is important to provide an effective therapeutic plan, intraoperative guidance, prognosis, and counseling. The preoperative management consists of gaining history and ophthalmic examination, neuroimaging to determine the characteristics of IOFB, and consideration of antimicrobial usage. In addition to clinical examination at the slit-lamp and indirect ophthalmoscopy, various imaging modalities are valuable for the identification and localization of IOFB.

\*Correspondence to :  
Mega Wulan Purnama Sari,  
Department of Ophthalmology,  
Padjadjaran University,  
Cicendo Eye Hospital  
megawulanps@gmail.com

Operative considerations include timing of surgery, the need for lens extraction, the route and instruments used for IOFB extraction, and antibiotics used intraoperatively. Postoperative care includes evaluation, prevention, and treatment of any complication and another further plan.

This case report presents the clinical and diagnostic finding, management, outcomes and further plan of the patient with IOFB.<sup>1-3,5</sup>

## CASE REPORT

### CASE 1

A 52-year-old male patient came to emergency unit at Cicendo Eye Hospital on December 16, 2017 with a chief complaint of blurry vision in right eye since 1 day ago and progressively worsen. The patient also complained pain, red eye, and lacrimation. There was history of ocular trauma 1 day before admission, hit by piece of wood when do the lawn. There were no history of loss of consciousness, nausea, vomiting, or bleeding from ear, nose and throat. The patient went to local hospital, and then referred to Cicendo Eye Hospital.

The general examination revealed high blood pressure 158/94 mmHg. Ophthalmological examination revealed visual acuity of the right eye was light perception with poor projection in all directions and the left eye was 1.0. The eye movements were within normal limit on the left eye and slight restriction to temporal, and inferotemporal due to chemosis of conjunctiva on the right eye. The intraocular pressure on the right eye was 32 mmHg, and the left eye was 15 mmHg. The anterior and posterior segment of the left eye was within normal limit, with no reversed relative afferent pupillary defect (RAPD). On the right eye there were scleral wound at nasal sclera  $\pm$  4 mm, chemosis, corneal edema and abrasion, anterior chamber Van Herick (VH) grade III with flare/cell hardly to seen. The pupil was round, decreased of pupillary reflex and no RAPD. Iris and lens within normal limit. Posterior segment cannot be seen due to haze media. From the USG examination there were opacity of vitreous suggest vitreous hemorrhage + intraocular foreign body with endophthalmitis. Plain X ray imaging of patient's head revealed right intraocular foreign body.

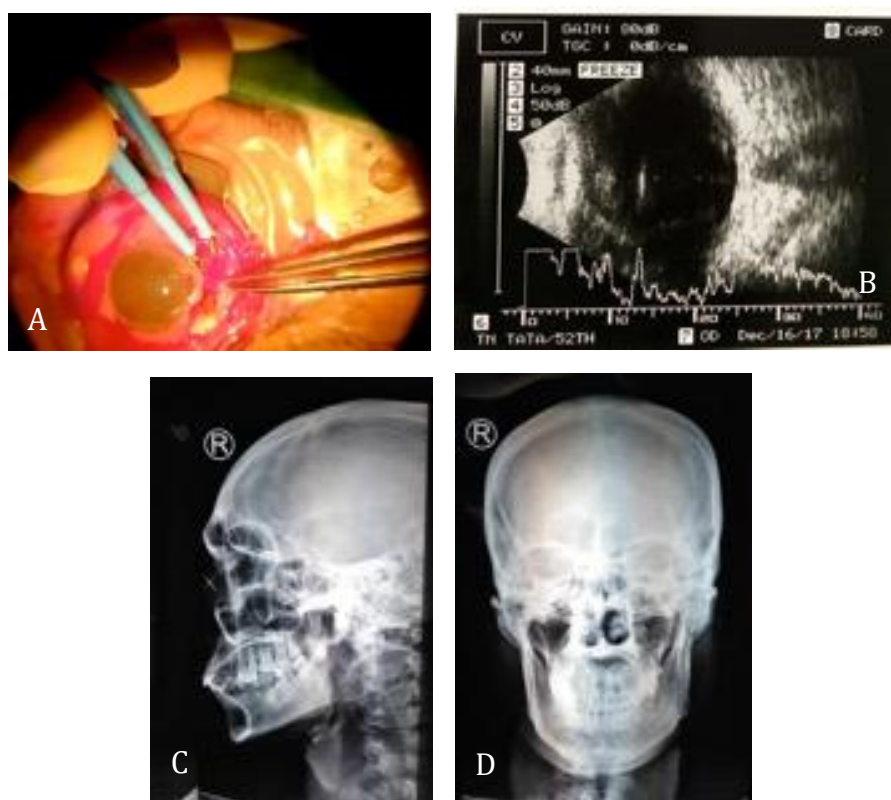


Figure 2.1 Intraocular foreign body. A. Scleral wound. B, C and D. USG and plain X ray showed intraocular foreign body

The patient were diagnosed as open globe injury type IOFB grade D, negative RAPD, Zone II with endophthalmitis, secondary glaucoma of the right eye. The patient was given oral anti glaucoma and antitetanus serum/tetanus toxoid. The patient underwent pars plana vitrectomy, IOFB extraction, endolaser, endodrainage, membrane peeling, vitreous tap, aquos tap, wash out anterior chamber, intravitreal antibiotic and dexamethasone injection, scleral repair, and silicone oil tamponade of the right eye.

During the exploration of the wound durante op, intraocular foreign body was found, black long iron measured 13 x 1 mm was extracted using forcep, and the sclera was sutured. During posterior segment surgery, retinal detachment and vitreous hemorrhage was identified. Pars plana vitrectomy, endodrainage, and endolaser were undergone. Silicone oil was injected to tamponade the detached retina. The retina was fully attached.



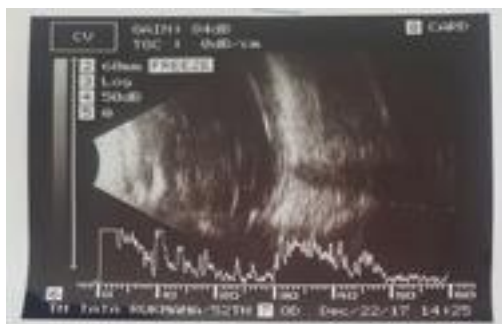**Figure 2.2 IOFB extracted from posterior segment**

Ceftriaxone 2x1 gram, methylprednisolone 1x56 mg, ranitidine 2x50 mg, paracetamol 3x500 mg, acetazolamide 3x250 mg, kalium aspartate 1x1 tab, moxifloxacin eye drop 6xRE, prednisolone acetate eye drop 6xRE, cyclophentolate 1% eye drop 3xRE, timolol 0,5% eye drop 2xRE was given after surgery.

The patient was discharged from hospital four days after surgery. He controlled on December 22th, 2017, 1 week after surgery. His visual acuity was light perception with good projection in temporal on the right eye. Intraocular pressure with palpation was slightly minus. Examination of the anterior segment for the left eye was found slightly blepharospasm, conjunctival and ciliary injection, corneal

edema, and VH gr.III with flare/cell +4/+4, fibrin and hazy lens of the right eye. Funduscopy of the left eye showed hazy media. Ultrasonography showed vitreous opacity suggest fibrosis vitreous, inflammation cell and silicon oil filled eye (Figure 2.3). The patient then diagnosed with endophthalmitis (resolved) + complicated cataract + SO filled eye of the right eye.

1 month after surgery patient came to follow up. His visual acuity was 1/300 on the right eye. Intraocular pressure with palpation was normal. Examination of the anterior segment for the right eye was found corneal scar, and hazy lens of the right eye with minimal inflammation of anterior chamber.



**Figure 2.3 USG examination 1 week after surgery**

**CASE 2**

A-47-year-old male patient came to vitreoretinal unit at Cicendo Eye Hospital on November 30, 2017 with a chief complaint of blurry vision in right eye since 1 week ago and progressively worsen. The patient also complained pain, red eye, and lacrimation. There was history of ocular trauma 1 week ago, hit by piece of stone when do the lawn. There were no history of loss of consciousness, nausea, vomiting, or bleeding from ear, nose and throat. The patient went to local hospital, and then referred to Cicendo Eye Hospital.

The general examination was within normal limit.. Ophthalmological examination revealed visual acuity of the right eye was 1/300 and the left eye was 1.0. The eye movements were within normal limit on both eyes. The

intraocular pressure on the right eye was 10 mmHg, and the left eye was 16 mmHg. The anterior and posterior segment of the left eye was within normal limit, with no reversed relative afferent pupillary defect (RAPD). On the right eye there were, ciliary injection, corneal leucoma suggest post corneal rupture, anterior chamber VH grade III with flare/cell +3/+3, hipopion ±1mm. The pupil was irregular with posterior sinechia, decreased of pupillary reflex and hazy lens. Posterior segment cannot be seen due to haze media. From the USG examination there were opacity of vitreous suggest fibrosis vitreous, inflammation cell differential diagnosed endophthalmitis and suggest IOFB. Plain X Ray imaging of patient's head revealed right intraocular foreign body.

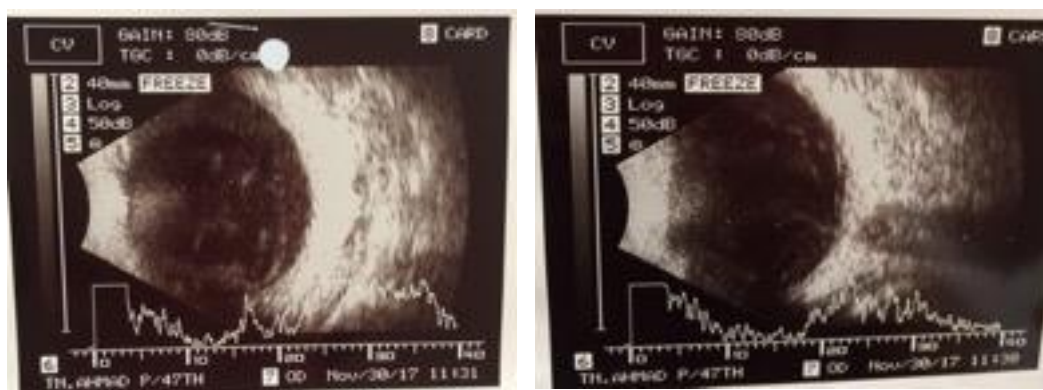


Figure 2.4 USG suggest intraocular foreign body

The patient were diagnosed as open globe injury type rupture grade D, negative RAPD, Zone I with endophthalmitis and traumatic cataract of the right eye. The patient underwent Small Incision Cataract Extraction (SICE), pars plana vitrectomy, IOFB extraction, vitreous tap, wash out anterior chamber, intravitreal antibiotic of the right eye.

During the exploration of the wound, Intraocular foreign body was found, a stone measured 2 x 0,5 mm was extracted using forcep. The retina was fully attached. Ceftriaxone 2x1 gram, methylprednisolone 1x48 mg, ranitidine 2x50 mg, paracetamol 3x500 mg, moxifloxacin eye drop 6xRE, prednisolone acetate eye drop 6xRE, cyclophentolate 1% eye drop 3xRE, was given after surgery.

The patient was discharged from hospital two days after surgery. He controlled on December 7th, 2017, 1 week

after surgery. His visual acuity was 1/60 on the right eye. Intraocular pressure was within normal limit. Examination of the anterior segment for the left eye was found slightly blepharospasm, conjunctival and ciliary injection, hecting cornea intact, and aphakia on the left eye. Funduscopy of the right eye showed attached retina. Ultrasonography showed vitreous opacity suggest inflammation cell. The patient then diagnosed with aphakia and resolved endophthalmitis of the right eye.

On January 11th, 2018 patient came to follow up. His visual acuity was 2/60 on the right eye and 1.0 on the left eye, from the refractive correction, visual acuity was 1.0 of the right eye with S+13.00 C-1.50x80 but he felt dizzy, so he was planned to secondary IOL (iris claw) but he refused.

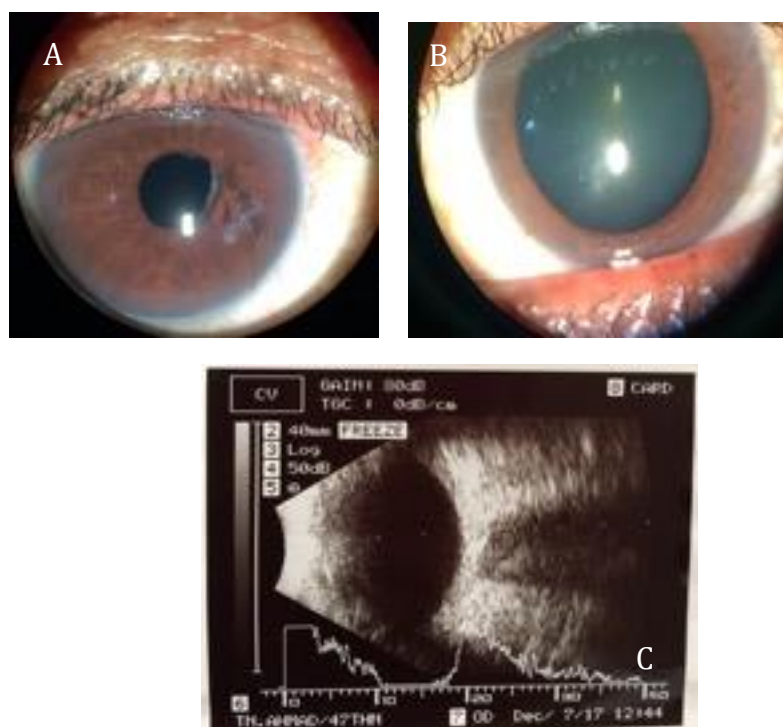


Figure 2.5 A and B anterior segment post operation (January 11th, 2018 ) C. USG showed mild vitreous opacity

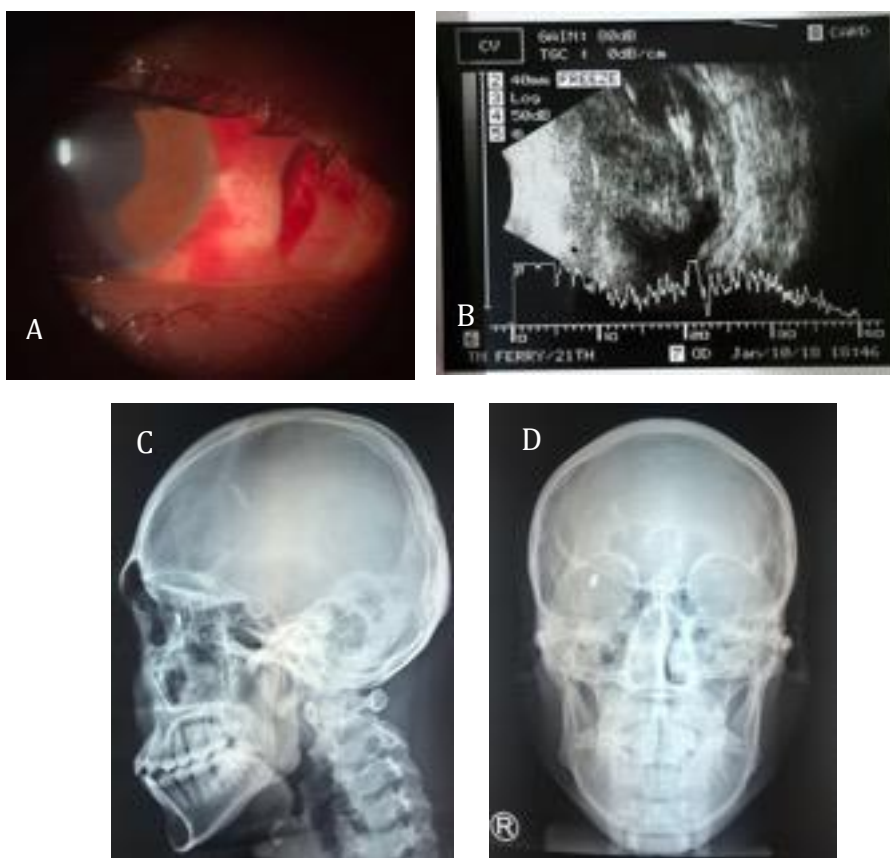


**CASE 3**

A-21-year-old male patient came to emergency unit at Cicendo Eye Hospital on January 10, 2018 with a chief complaint of blurry vision in right eye since 1 hour ago. The patient also complained red eye, and lacrimation. There was history of ocular trauma 1 hour before admission, hit by piece of iron when hammering. There were no history of loss of consciousness, nausea, vomiting, or bleeding from ear, nose and throat.

The general examination was within normal limit. Ophthalmological examination revealed visual acuity of the right eye was 1/300 and the left eye was 1.0. The eye movements were within normal on both eyes. The intraocular pressure on the right eye had not been

examined and the left eye was 15 mmHg. The anterior and posterior segment of the left eye was within normal limit, with no reversed relative afferent pupillary defect (RAPD). On the right eye there were, scleral wound at nasal sclera  $\pm$  4 mm from limbus 5x2 mm, vitreous prolapse, chemosis, corneal edema, anterior chamber VH grade III with flare/cell +4/+4, fibrin. The pupil was round, decreased of pupillary reflex and with no RAPD. Iris and lens within normal limit. Posterior segment cannot be seen due to haze media. From the USG examination there were opacity of vitreous suggest vitreous hemorrhage + suggest intraocular foreign body. Plain X ray imaging of patient's head revealed right intraocular foreign body.



**Figure 2.6 Intraocular foreign body. A. Scleral wound. B, C and D. USG and plain X ray showed intraocular foreign body**

The patient were diagnosed as open globe injury type IOFB grade D, negative RAPD, Zone II with vitreous hemorrhage of the right eye. The patient was given antitetanus serum/tetanus toxoid. The patient underwent pars plana vitrectomy, scleral repair, gas C3F8 of the right eye.

During posterior segment surgery, retinal detachment and vitreous hemorrhage was identified and intraocular foreign body was hardly to find. There were massive

choroidal detachment, hole at posterior pole and emphysema subretina. Gas (C3F8) was injected to tamponade the detached retina. Cefotaxime 2x1 gram, paracetamol 3x500 mg, moxifloxacin eye drop 6xRE, prednisolone acetate eye drop 6xRE, cyclophentolate 1% eye drop 3xRE, methylprednisolone 4x125 mg was given after surgery. From the Plain X ray imaging of patient's head one day after surgery still revealed right intraocular foreign body.

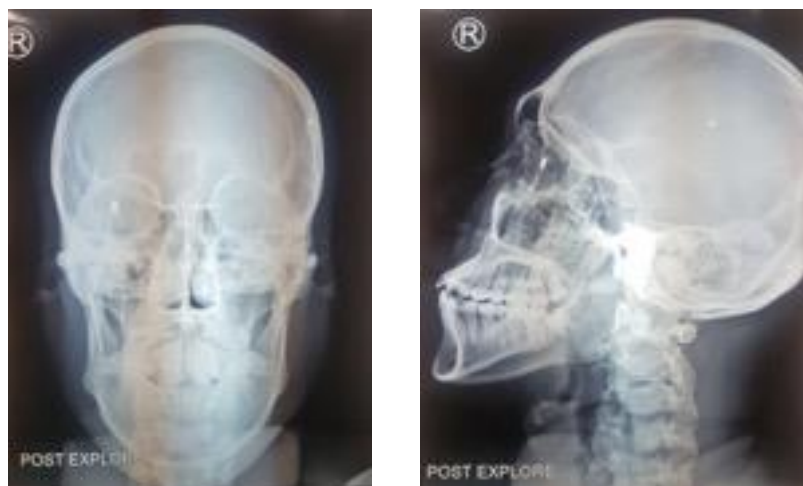

Figure 2.7 Plain X-ray Post explore

The patient was discharged from hospital three days after surgery. He controlled on December 19th, 2017, 1 week after surgery. His visual acuity 1/300 on the right eye. Intraocular pressure with palpation was within normal limit. Examination of the anterior segment for the right eye was found slightly blepharospasm, conjunctival and ciliary injection, corneal edema, anterior chamber VH gr.III, flare/cell +2/+2 on the right eye. Funduscopy of the right eye showed hazy media in inferior suggest vitreous hemorrhage, attached retina with gas bubble. The patient then diagnosed with retained IOFB + attached retina + gas filled eye of the right eye. Patient was planned to do

CT-Scan examination for further evaluation and management.

On February 2nd, 2018 patient came to follow up. The CT-Scan evaluation still had not done. His visual acuity was 1/300 on the right eye. Intraocular pressure with palpation was slightly minus. Examination of the anterior segment was good with mild inflammation of anterior chamber flare/cell  $\pm/\pm$  on the right eye. Funduscopy of the right eye showed hazy media suggest vitreous hemorrhage. From the USG examination still suggested intraocular foreign body with preptisis bulbi. Patient was planned to do CT-Scan examination.

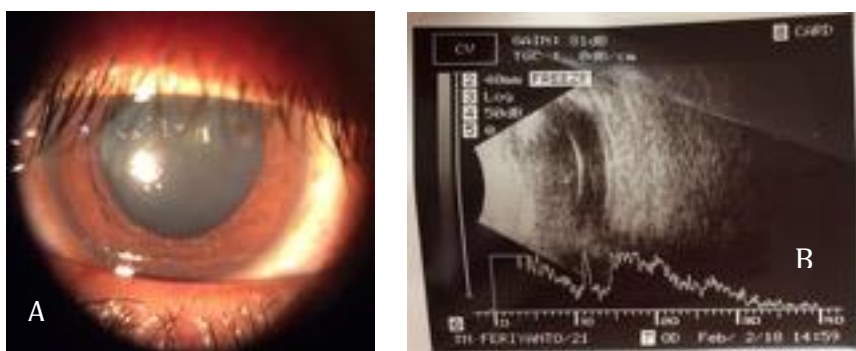


Figure 2.8. A. Anterior segment. B. USG showed preptisis bulbi

## DISCUSSION

Intraocular foreign body (IOFB) injuries vary in presentation, outcome, and prognosis depending upon various factors. Apart from the prominent feature of IOFB retention, IOFBs also include common characteristics of penetration, rupture, or perforation, depending on the mechanism of injury. Foreign bodies that lie intraocularly are penetrating and can enter through the cornea (65%), sclera (25%), or at the limbus (10%). These foreign bodies

are usually seen in the posterior segment in most (58%-88%) cases, with most others in the anterior chamber (10%-15%) or the lens (2%-8%). A literature review conducted by Kuhn and colleagues has shown that, in penetrating injuries, multiple IOFBs can be found in 8%-25% of eyes, with an average size of an IOFB of 3.5 mm (range: 0.5-25 mm). The composition of IOFBs varies from organic material (e.g., insect parts and animal hairs), glass, plastic, or metals such as zinc, nickel, aluminum, mercury, iron, and copper.<sup>1,6-8</sup>

Because of the multitude of potential findings, prompt and full assessment of patients with possible IOFB retention based on the early signs is important to provide an effective therapeutic plan, intraoperative guidance, prognosis, and counseling. The treatment aim is effective repair of ocular abnormalities while avoiding complications, such as endophthalmitis, resulting from insufficient evaluation or unnecessary treatment, such as enucleation, resulting from erroneous judgment. The preoperative evaluation should include a focused history to determine the time and mechanism of the injury along with detailed information about the composition of the object. For liability reasons, it is important to note whether the injury occurred in the workplace and whether the patient was wearing protective eyewear when the injury occurred.<sup>1,6,7</sup>

The extent of intraocular damage caused by IOFBs depends on several factors. Wound length can be used to predict the risk of retinal injury. A shorter wound means that less of the IOFBs energy is dissipated during penetration and may travel much further inside the eye, allowing it to reach and injure the retina. Foreign bodies entering the eye through the sclera are more likely to cause intraocular damage than those entering through the cornea. Object shape can also be predictive of intraocular damage. Sharp IOFBs cause less damage than blunt ones of the same size. This is presumably due to the increased transfer of energy to the eye at the time of impact by blunt IOFBs as opposed to sharp IOFBs, which often enter through a smaller linear laceration.<sup>1,2,8</sup>

A complete examination of the ocular and surrounding structure should be performed. Baseline visual acuity, pupillary reaction, intraocular pressure, slit-lamp biomicroscopy, assessment of media clarity, extent of the wound, iris color, lens status, presence of retinal tears and detachments, and signs of endophthalmitis should be examined. If possible, the size, shape, location, number, type, magnetic properties, and entry path of a foreign body should be described.

Ocular imaging is a vital tool for management of IOFBs. Historically, ultrasonography, B-scan, X-ray imaging, CT, and MRI have been the adjunct imaging tools used in detection of IOFBs. The appropriate diagnostic tool for visualization and localization depends on the suspected composition and location of the IOFB. Computed

Tomography (CT) scan with 1 mm section and no contrast can be chosen to detect metallic and nonmetallic material. Plain film can fail to identify up to 60 % of the time metallic foreign bodies, but still an inexpensive and readily obtainable. Ultrasonography (USG) is user dependent but can be up to 98% sensitive in detecting IOFBs. USG can also detect retinal detachment, hemorrhage, sign of endophthalmitis, and identify scleral wound entry. Magnetic Resonance Imaging (MRI) can be used after the presence of metallic IOFB is ruled out.<sup>1-3,5,6,8</sup>

In these cases, all of patients were men in age range 20-55 years old. There were history ocular trauma of the right eye that happened at workplace. There were also loss of vision, pain, redness, and from ophthalmological examinations revealed penetrated scleral injury and corneal injury that suggest an IOFB in posterior segment. The plain x ray film examinations showed intraocular foreign body in the right eye all of the patient. The USG examination also showed intraocular foreign body in the right eyes. CT scan and MRI were not done because of availability. Two of patients were suggest endophthalmitis post traumatic from ocular and diagnostic finding.

Timing of the surgery is determined by several factors, such as overall health status of the patients (presence of life threatening injury and ability to tolerate the surgery), the nature of the injury (farm injuries are more likely causing endophthalmitis than heat sterilized missiles), the composition of the IOFB (pure copper induced intense inflammatory response meanwhile glass IOFB remained inert), and availability of the surgeons and the required equipment. Yeh et al had proposed the potential advantages of immediate IOFB removal, such as decreased the risk of endophthalmitis, decreased the rate of proliferative vitreoretinopathy (PVR), and single procedure for the patient. Post traumatic infection and the presence of an IOFB are likely to increase the risk of PVR. Definitive treatment involves vitrectomy, removal of the IOFB, and intravitreal as well as systemic antibiotic therapy.<sup>7-10</sup>

In these cases, the incident had caused endophthalmitis in two patients and prolapse of intraocular content in one patient, the surgeon and equipment required were available. The surgery was performed within 24 hours after admission

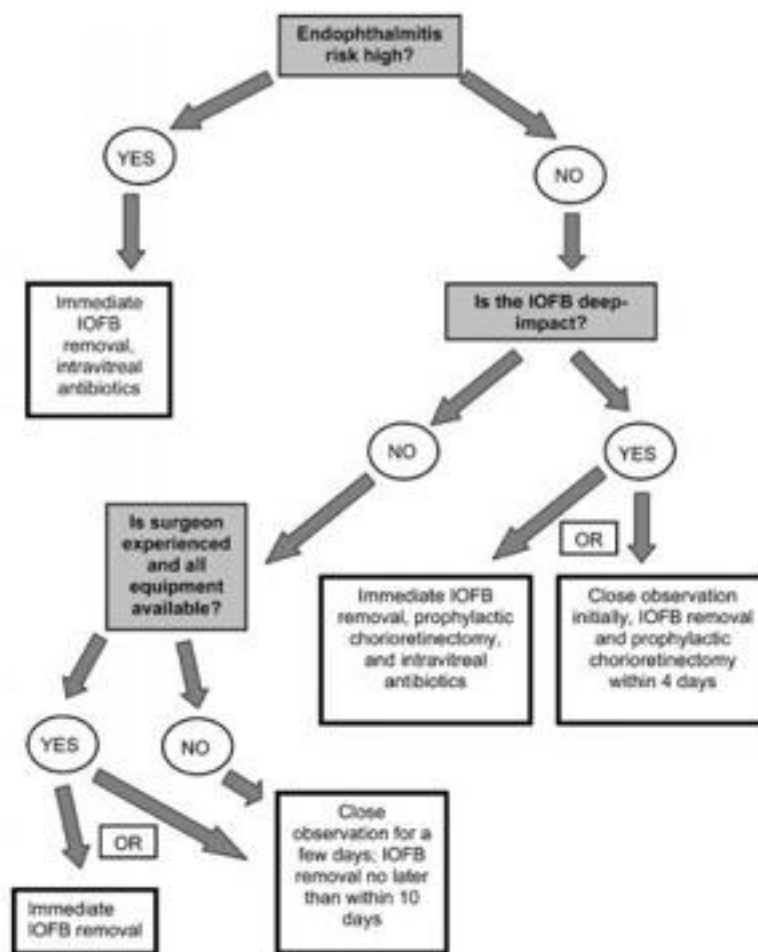


Figure 3.1 Flowchart showing the timing recommendations for eyes with IOFB injury

Source: Kuhn<sup>6</sup>

The chosen method to extracted IOFB depends on several considerations such as the location, composition, size of the IOFB, and also the presence of other ocular abnormalities including cataract, endophthalmitis, vitreous hemorrhage, retinal tear, and retinal detachment. Three instruments are commonly available for IOFB extraction are external magnets, intraocular forceps, and intraocular magnets. External magnets are best reserved for cases in which extraction can be performed immediately (success rates fall when the IOFB becomes encapsulated). When a magnetic intravitreal foreign body can be well visualized, extraction with an external electromagnet is usually effective. This should be done through a pars plana sclerotomy after repair of the entry site. It is important to make the sclerotomy large enough so that the foreign body can pass out of the globe without becoming incarcerated in the pars plana. If the scleral laceration site is used for extraction, then it should be enlarged, since the elastic sclera and ocular tissues will have stretched after initial IOFB entry and made the wound smaller than the longest dimension of the IOFB. A magnetic extraction is best performed with an assistant holding the magnet over the sclerotomy while the

surgeon visualizes the IOFB with indirect ophthalmoscopy and controls the magnet's foot pedal. If a large sclerotomy is needed, it is helpful to pre-place a mattress suture so that it can be closed quickly after removal of the IOFB to decrease the period of hypotony.<sup>8,9</sup>

In this case report, the IOFB of first and second patients were found in the posterior segment and could be seen durante operation. The removal were done using forcep. The sclera of the first patient and the cornea of the second patient were sutured. During posterior segment surgery, retinal detachment and vitreous hemorrhage from the first patient was identified. Pars plana vitrectomy, endodrainage, and endolaser were undergone. Silicon oil tamponade and gas was injected to vitreous cavity. Intravitreal antibiotic was administered due to endophthalmitis in these two patients. For the third patient, the IOFB could not be found durante operation. Retinal detachment and vitreous hemorrhage was identified. There were also massive choroidal detachment, hole at posterior pole and emphysema subretina. Gas (C3F8) was injected to tamponade the detached retina. All of these finding suggested perforated wound with the IOFB being trapped in the sclera or



outside the ocular. The patient need further evaluation and examination.

The focus of postoperative care is prevention or treatment of complications, such as endophthalmitis, retinal detachment, and PVR. Loporchio et al recommend administration of 2 to 5 days of intravenous vancomycin and ceftazidime followed by 7 to 10 days of oral ciprofloxacin or levofloxacin for open globe injury with an IOFB. Two of the patients in these cases were already suggest endophthalmitis. Intravenous ceftriaxone followed by oral ciprofloxacin were administered as a treatment for endophthalmitis.<sup>11-13</sup>

The presence of an IOFB affects visual prognosis in

three ways: (1) in the structural damage induced by the IOFB (e.g., retinal tear); (2) as a vehicle for delivery of infectious agents; and (3) in the chemistry of the IOFB (e.g., pure copper is very inflammatory). Preoperative or postoperative retinal detachment, and PVR are also the prognostic factors associated with poor functional and anatomic outcomes. Early detection and surgical treatment can be tried to overcome these complications. Kuhn and colleagues developed the Ocular Trauma Score System to predict the expected visual. The sum of the numbers relates to an OTS category, based on which the expected visual acuity, divided into five meaningful categories, can be identified.<sup>14,15</sup>

**Table 3.1 Ocular Trauma Score variables and raw points<sup>14</sup>**

Variable	Raw points
Initial vision	
No light perception	60
Light perception	70
1/200-19/200	80
20/200-20/50	90
≥20/40	100
Rupture	-23
Endophthalmitis	-17
Perforating injury	-14
Retinal detachment	-11
Afferent pupillary defect	-10

**Table 3.2 Ocular Trauma Score category and predicted final visual acuity<sup>14</sup>**

Sum of raw points	OTS	No light perception	Light perception/ hand motion	1/200-19/200	20/200-20/50	≥20/40
0-44	1	74%	15%	7%	3%	1%
45-65	2	27%	26%	18%	15%	15%
66-80	3	2%	11%	15%	31%	41%
81-91	4	1%	2%	3%	22%	73%
92-100	5	0%	1%	1%	5%	94%

First patient had initial visual acuity of light perception, retinal detachment, and endophthalmitis. Based on the OTS, the patient had 42 points indicating poor visual acuity prognosis. Second patient had initial visual acuity of 1/300, corneal rupture and endophthalmitis. The score of this patient was 40 points. Evaluation post operation for this patient had a good progress. Third patient had initial visual acuity of 1/300, retinal detachment, and suggest perforating injury with OTS score 55 points, however this patient still had retained IOFB that could not be found durante operation and the eye that already preptisis. The prognosis for this patient is ad malam. Patient was planned to do CT-Scan examination for further evaluation and management.

**CONCLUSION**

Intraocular foreign body (IOFB) injuries vary in presentation, outcome, and prognosis depending upon various factors. The evaluation of the patient with suspected intraocular foreign body including complete history, examination, and ocular imaging. Timing of the surgery should be decided carefully based on advantages and disadvantages of the planned surgery. Method of IOFB extraction should be chosen based on several considerations. Postoperative measures focus on preventing and treating the possible complications. Prompt treatment and full assessment of patients is important to provide good prognosis.

## REFERENCES

1. Loporchio D, Mukkamala L, Gorukanti K, Zarbin M, Langer P, Bhagat N. Intraocular foreign bodies: A review. *Survey of ophthalmology* 61. 2016;582-96
2. Zhang Y, Zhang M, Jiang C, Qiu HY. Intraocular foreign bodies in China: clinical characteristics, prognostic factors, and visual outcomes in 1,421 eyes. *Am J Ophthalmol.* 2011;152 : 66-73
3. Yeh S, Colyer MH, Weichel ED. Current trends in the management of intraocular foreign bodies. *Curr Opin Ophthalmol.* 2008; 19:225-33
4. Parke III DW, Flynn Jr HW, Fisher YL. Management of intraocular foreign bodies: a clinical flight plan. *Can J Ophthalmol.* 2013; 48:8-12
5. Lemley CA, Wirostko WJ, Mieler WF, McCabe CM and Dieckert JP. Intraocular Foreign Bodies. In: Albert DM, Miller JW, Azar DT, Blodi BA, Cohan JE, Perkins T. *Albert & Jakobiec's Principles & Practice of Ophthalmology.* Third edition. Philadelphia: Saunders; 2008. p. 5137-45
6. Kuhn F, Pieramici DJ. Intraocular foreign bodies, In: Ferenc K, Pieramici D (eds) *Ocular Trauma: Principles and Practice.* New York, Thieme; 2002, p. 235-63
7. Kuhn F. Penetrating injuries and IOFB. In: Kuhn F. *Ocular traumatology.* Leipzig: Springer; 2008. p. 371-88
8. Rathod R, Mieler WF. An update on the management of intraocular foreign bodies. *Retin Physician.* 2011;8(3):52e5
9. Cantor LB, Rapuano CJ, Cioffi GA. Retina and vitreous. In: *Basic and clinical science course.* San Francisco: American academy of ophthalmology; 2014. p. 325-8
10. Recchia FM, Sternberg P. Surgery for ocular trauma: Principles and techniques of treatment. In : Ryan SJ, Sadda SR, Hinton DR, Schachat AP, Wilkinson CP, Wiedemann P. *Retina.* Fifth edition. Philadelphia:Saunders. 2013. p.1861-5
11. Chaudhry, I.A., Shamsi, F.A., Al-Harhi, E. et al. Incidence and visual outcome of endophthalmitis associated with intraocular foreign bodies. *Graefes Arch Clin Exp Ophthalmol.* 2008; 246: 181
12. Colyer MH, Weber ED, Weichel ED, Dick JS, Bower KS, Ward TP, et al. Delayed intraocular foreign body removal without endophthalmitis during operations Iraqi freedom and enduring freedom. *Ophthalmol.* 2007;114: 1439-47
13. Katz G, Moisseiev J. Posterior-segment intraocular foreign bodies: An update of management. *Retinal physician.* 2009.
14. Kuhn F, Maisiak R, Mann L, Mester V, Morris R, Witherspoon CD. The ocular trauma score (OTS). *Ophthalmol Clin N Am* 15. 2002; p. 163-5
15. Williams DF, Mieler WF, Abrams GW, Lewis H. Results and prognostic factors in penetrating ocular injuries with retained intraocular foreign bodies. *Ophthalmology.* 1988;95(7):911-6



This work licensed under Creative Commons Attribution