

BRANCH RETINAL VEIN OCCLUSION WITH VITREOUS HEMORRHAGE IDENTIFIED DURING INTRAOPERATIVE VITRECTOMY

Nafila Mahida Sukmono¹, Ramzi Amin^{1,2}

¹Ophthalmology Department, Universitas Sriwijaya

²Mohammad Hoesin Hospital Palembang

ABSTRACT

Introduction Retinal vein occlusion is the largest group of retinal blood vessels after diabetic retinopathy. Occlusion occurring in the retinal vein is divided into central retinal vein occlusion (CRVO) occlusion and branch retinal vein occlusion (BRVO) occlusion. The Beijing Eye Study, reported a higher incidence of BRVO than CRVO, where 10-year incidents for BRVO were 1.6 per 100 subjects, and CRVO was only 0.3% 100 subjects.¹ To report a case of Branch Retinal Vein Occlusion with vitreous hemorrhage identified during intraoperative vitrectomy

Method: A 49-year-old woman with a history of 15 years of hypertension had right eye vision complaints, increasingly blurred since last 2 months. The right eye visual acuity 2/60 cannot be corrected and left eye 6/30 cannot be corrected. The posterior segment on right eye is difficult to assess. USG B-Scan right eye found vitreous echospike appearance of vitreous bleeding. We manage with vitrectomy and during intraoperative we identified bleeding and ghost vessel in superotemporal area. Bleeding in the superotemporal quadrant is done by photocoagulation laser action.

Results: First day postoperative there was increased in visual acuity to 6/60 with a posterior segment that could be assessed, obtained tortuous blood vessels, slight bleeding and ghost vessel in the superotemporal area with laser injury.

Conclusion: In this case report, patients with BRVO with complications of vitreous hemorrhage performed vitrectomy with additional endolaser in the ischemic area. The result of this action of visual acuity improvement in patient.

Keywords: Retinal vein occlusion, Branch retinal vein occlusion, Vitreous Hemorrhage

Cite This Article: SUKMONO, Nafila Mahida. Branch Retinal Vein Occlusion with Vitreous Hemorrhage Identified During Intraoperative Vitrectomy. International Journal of Retina, [S.l.], v. 1, n. 1, July 2018. ISSN 2614-8536. Available at: <<https://www.ijretina.com/index.php/ijretina/article/view/37>>

INTRODUCTION

Retinal vein occlusion is the largest group of retinal blood vessels after diabetic retinopathy. Occlusion occur in the retinal vein is divided into central retinal vein occlusion (CRVO) occlusion and branch retinal vein occlusion (BRVO) occlusion. The Beijing Eye Study, reported a higher incidence of BRVO than CRVO, where 10-year incidents for BRVO were 1.6 per 100 subjects. Based on Branch Retinal Vein Occlusion study (BVOS), the prognosis for BRVO is better than CRVO. Precisely 50-60% of unadjusted BRVO cases have visually enduring onset, even improving \geq 6/12 after one year.

So, when patients with mild visual impairment due to macular edema caused by BRVO, enough observation in the first 3 months to see the progress of the situation. However, in some patients the symptoms may arise late and there may be more severe visual impairment. In this condition, only 18-41% of spontaneous improvement with an average visual acuity of 6/12 is recommended for early therapy.¹ Macular edema and neovascularization are major complications of BRVO requiring treatment.

*Correspondence to:

Nafila Mahida Sukmono,
Department of Ophthalmology,
Sriwijaya University,
nafisukmono@gmail.com

In macular edema, photocoagulation lasers, intravitreal steroid injections, or intravitreal injection of anti-vascular endothelial growth factor (VEGF) are present. Neovascularization of the disc or retina is an indication of photocoagulation in the ischemic region, although there is evidence to suggest that photocoagulation measures have no effect on visual prognosis in cases of vitamin A hemorrhage.² Vitrectomy is indicated in cases of vitreous bleeding that fails to spontaneous resolution after 6 weeks to 3 months. The timing of vitrectomy depends on the tendency of the ophthalmologist and the patient's visual needs.³

METHOD

A 49-year-old woman with a history of 15 years of hypertension had right eye vision complaints, increasingly blurred since last 2 months. The right eye visual acuity 2/60 cannot be corrected and left eye 6/30 cannot be corrected. The posterior segment on right eye is difficult to assess. Right Eye Ultrasonography B-Scan found vitreous echospike appearance leads of vitreous bleeding. We manage with vitrectomy and during intraoperative we identified bleeding and ghost vessel in superotemporal area. Bleeding in the superotemporal quadrant is done by photocoagulation laser action.

RESULTS

First day postoperative there was increased in visual acuity to 6/60 with a posterior segment that could be assessed, obtained tortuous blood vessels, slight bleeding and ghost vessel in the superotemporal area with laser injury.

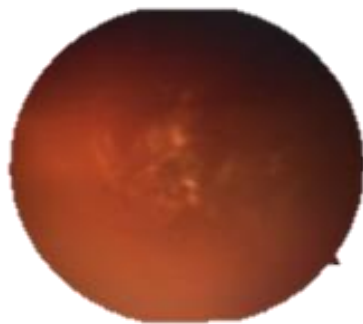


Figure 1. Fundus Imaging of Right Eye Before Surgery

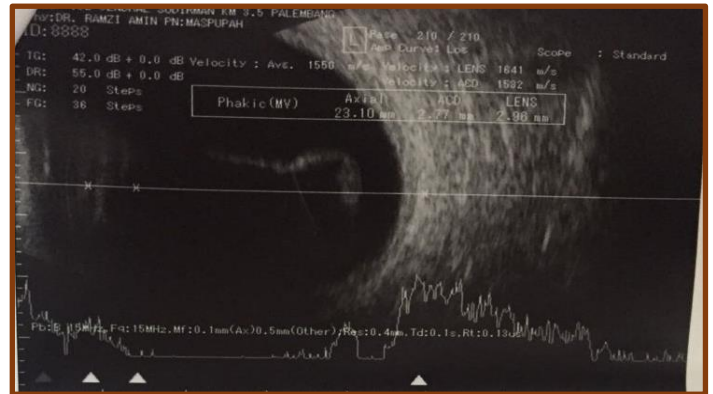


Figure 2. Ultrasonography B-Scan

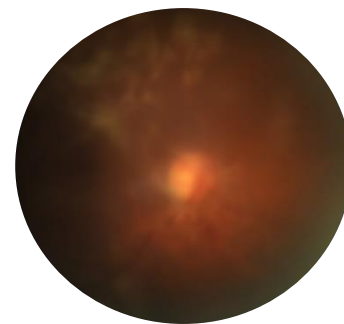


Figure 3. Fundus Imaging of Right Eye After Surgery

DISCUSSION

Anamnesis, disease history and ophthalmological examination and investigation are important to explore information on the onset, causes and predisposing factors. All of this information can be helpful in making the diagnosis and planning a management. It has been reported that a 49-year-old woman with right eye complaints suddenly escaped ± 6 months ago. More or less 6 months ago the patient complained of seeing her right eye suddenly felt blurred with complaints when seen as shaded. Vision continues to decline without any improvement. Pain around the eyes accompanied by dizziness is absent, red eyes are absent, the patient never sees flashes of light and eyesight like closed curtains do not exist. More or less 2 weeks ago the patient complained that her right eye was getting blurred without red eyes. Abnormalities as mentioned above resemble the clinical picture of retinal vein occlusion, where there is a symptom of sudden, painless and non-reddened vision loss. In the literature, retinal vein occlusion is the largest group of retinal blood vessels after hypertensive retinopathy and diabetic retinopathy.

Occlusion occurring in the retinal vein is divided into central retinal vein occlusion (Occlusion) and retinal vein occlusion (Branch Retinal Vein Occlusion). BRVO is common in arterial and venous crosses, which is marked by a 90% unilateral, unusually sharp decrease of vision, sudden and painless.

The patient visual acuity is 2/60 ph (-) on the left eye and 6/30 on the right eye. Examination of the right eye posterior segment in these patients is difficult to assess, from the examination of ultrasonography b-scans obtained vitreous echospikes, retina traction (+). In these patients there is a right-sided bleeding of the vitreous which is most likely due to BRVO. During intraoperative right eye, the condition is found in accordance with the literature which expresses a typical feature of BRVO that is edema, retinal hemorrhage scattered in a triangle-shaped area with apices in place of occlusion, veins with obstruction seen dilated and weaved distally from the occlusion site, the associated usually looks narrow and sclerotic, cotton wool spot that appears to indicate the presence of ischemia. OCT testing is helpful for assessing macular edema, fovea thickness and cystoid changes associated with BRVO.

However, this patient has not been able to perform an OCT examination and is planned to be performed after 1-week control. OCT is a rapid and noninvasive tool and is an important tool as a follow-up check for progress of therapy. From several studies it was shown that the thickness of the macula shown by OCT in BRVO patients was associated with sharp eyesight. Improvement of the visual acuity also shows good progress, where the patient comes with a 3/60 ph (-), visual acuity and becomes 4/60 ph (-). The more distal the occlusion of the optic disc, the better the prognosis. The state of the return of the visual acuity also depends on the amount of venous flow involved (which corresponds to the location and extent of

the occluded vein). The prognosis in this patient *quo ad functionam* is *dubia ad night* due to handling of the patient when it has arising complications of vitreous bleeding, so hopefully. In addition, risk factors in these patients are also found, namely in the form of hypertension then the more appropriate treatment can be performed on this patient. The size and location of BRVO, the presence or absence of retinal neovascularization and vitreous hemorrhage also determine the prognosis of this disease.

CONCLUSION

In this case report, patients with BRVO with complications of vitreous hemorrhage performed vitrectomy with additional endolaser in the ischemic area. The result of this action of visual acuity improvement in patient.

References

1. J.Q. Zhou, et al. *The 10-year incidence and risk factor of retinal vein occlusion the Beijing eye study*. *Ophthalmology*. 120: 803-808. 2013.
2. Branch vein occlusion study group. *Argon laser scatter photocoagulation for prevention of neovascularization and vitreous hemorrhage in branch vein occlusion. A randomized clinical trial*. *Arch Ophthalmol*. 104: 34-41. 2008.
3. *Retinal vein occlusion (RVO) guidelines*. The Royal College of Ophthalmologists. London. 2015.



This work licensed under Creative Commons Attribution