

CLINICAL OUTCOMES OF SURGERY FOR ADVANCED STAGE RETINOPATHY OF PREMATURITY: A CASE REPORT

Dian Estu Yulia, Marissa Jayawinata, Mario Marbungaran Hutapea

Department of ophthalmology, Faculty of Medicine, Universitas Indonesia, Cipto Mangunkusumo National Central Hospital Jakarta, Indonesia

Abstract

Introduction: Advanced stages of Retinopathy of Prematurity (ROP) could lead to childhood blindness and retinal surgery is needed as the main treatment. This case aims to report the clinical outcomes after surgery for advanced-stage ROP

Case Report: A female infant was admitted to the pediatric ophthalmology clinic in Cipto Mangunkusumo National Central Hospital Jakarta with a lack of visual contact in both eyes at 53 weeks of Post Menstrual Age (PMA). The infant was delivered at 28 weeks of gestational age with a birth weight of 1100 g. The baby was treated in NICU for 24 days and received oxygen therapy in the previous hospital. Retinal examination revealed that the patient had stage 5 ROP in the right eye and stage 4B ROP in the left eye. Furthermore, blinking reflect was absent in both eyes. Vitrectomy and endolaser were performed for the baby's left eye. Surgery was not conducted for the infant's right eye due to poor prognosis. Six weeks after surgery, the infant underwent examination under anesthesia (EUA) which showed that the retina was reattached with no vitreous hemorrhage, and intraocular pressure measurement was 7 mmHg. The result of the visual acuity test by Cardiff Acuity Cards was 6/60 on both eyes. Followed up EUA reported that the refraction test result on the left eye was S-3.75 C-5.75 x 85o and an undetermined result on the right eye due to opacity in the visual axis.

Discussion: Several surgeries have been described as the treatment of choice for advanced-stage ROP, including scleral buckling and vitrectomy with or without the addition of endolaser. Previous studies illustrated that stage 5 ROP has a low success rate on lens-sparing vitrectomy compared to stage 4A and 4B. The outcome success rate was the best in stage 4A ROP. Moreover, stage 4B ROP had a moderate success rate with sufficient visual outcomes.

Conclusion: The functional outcome of vitrectomy surgery may not equate to anatomic success. Retinal reattachment and moderate visual outcome were achieved by performing vitrectomy and endolaser in this case. Followed-up periodically is necessary for advanced stage ROP postoperatively.

Keywords: Stage 4 ROP, Stage 5 ROP, Vitrectomy, Visual Acuity

Cite This Article: YULIA, Dian Estu; JAYAWINATA, Marissa; HUTAPEA, Mario Marbungaran. CLINICAL OUTCOMES OF SURGERY FOR ADVANCED STAGE RETINOPATHY OF PREMATURITY: A CASE REPORT. International Journal of Retina, [S.l.], v. 6, n. 1, p. 67, mar. 2023. ISSN 2614-8536. Available at: <<https://www.ijretina.com/index.php/ijretina/article/view/210>>. doi: <https://doi.org/10.35479/ijretina.2023.vol006.iss001.210>.

Correspondence to:

Dian Estu Yulia,
Cipto Mangunkusumo
Hospital, Jakarta, Indonesia.
dianestu.dianestu@gmail.com

INTRODUCTION

Retinopathy of prematurity (ROP) is a vasoproliferative disease affecting preterm infants.¹ Estimation of ROP cases globally in 2010 was 184.700 babies, and 20.000 of them suffered from childhood blindness or severe visual impairment.² Probable higher risk for ROP was found in premature babies with live sustaining treatment in the Neonatal Intensive Care Unit (NICU).² More than 40% of preterm birth worldwide were collected from developing countries, including India, China, Bangladesh, Pakistan, and Indonesia.¹ Therefore, the risk of ROP cases scaled up in those countries.¹ Multicentre study of 34 hospitals in 17 major provinces in Indonesia showed that the incidence of all-stage ROP was 18% and severe ROP was 4%.³

The Early Treatment for Retinopathy of Prematurity (ETROP) study reported that type 1 ROP was indicated early management, such as laser ablation within 48 – 72 hours of the first diagnosis. However, some eyes treated progressed to stage 4 and 5 ROP.⁴ Surgical interventions, including scleral buckling and vitrectomy, were considered to treat advanced-stage ROP.⁵ Prior to the current standard treatment of lens-sparing vitrectomy, scleral buckling was the treatment of choice.⁶ Despite the controversy, scleral

buckling still had beneficial effects on the anterior traction of stage 4 ROP.⁷ Lens-sparing vitrectomy was best performed in ROP stage 4A due to the high rate of anatomical and vision outcome success.⁶ Meanwhile, in Jin Choi et al. study showed that the success rate of stage 4B and 5 ROP was 62% and 13%, respectively.⁸ Moreover, poor visual outcomes were found in stage 4B ROP despite successful retinal reattachment, and unfavorable outcomes were found in stage 5 ROP.⁸

This case aims to report the clinical outcomes after surgery for advanced-stage ROP.

CASE REPORT

A 53 weeks of PMA female infant presented to the pediatric ophthalmology clinic in Cipto Mangunkusumo National Central Hospital Jakarta with a lack of visual contact in both eyes. The baby had a history of spontaneous delivery at 28 weeks of gestational age with a birth weight of 1100 g. The infant had been managed in the Neonatal Intensive Care Unit (NICU) for 24 days in the previous hospital, during which the baby received oxygen therapy due to poor respiratory status. History of sepsis, blood transfusion, and heart disorder was denied. Ophthalmic examination demonstrated an absence of blink reflex on both eyes in response to light flash. RetCam® examination revealed stage 4B ROP in the left eye and stage 5 ROP in the right eye.

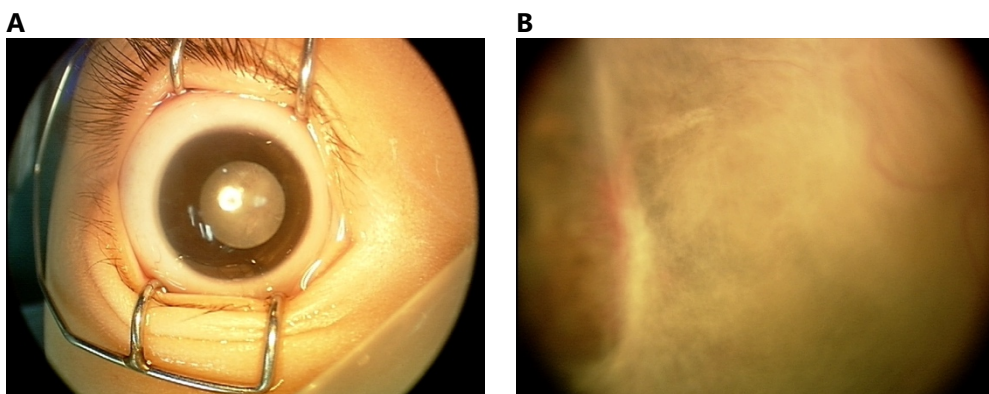


Figure 1. Right Eye A) Anterior segment photo in stage 5 ROP B) Fundus Photo showing total retinal detachment

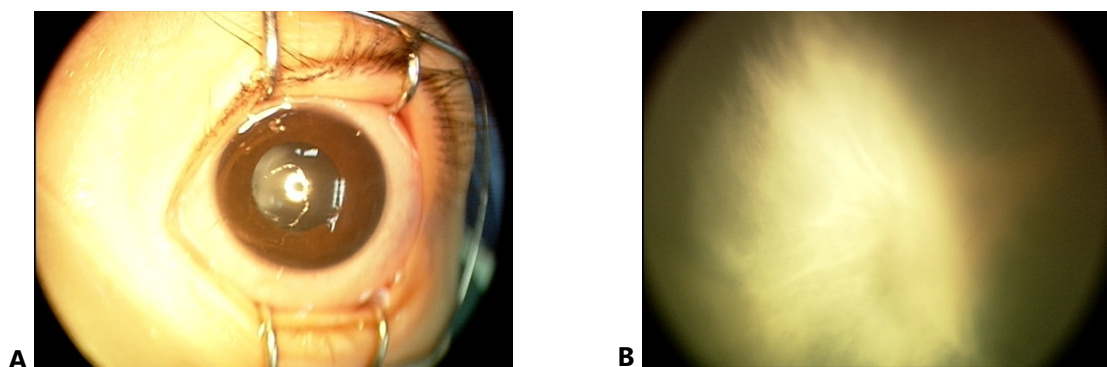


Figure 2. Preoperative findings of the left eye. A) anterior segment photo in stage 4B ROP patient. B) Fundus photo showing retinal detachment

The infant underwent vitrectomy and endolaser in the left eye under general anesthesia using laryngeal mask. This procedure commenced with traction released from the core to the peripheral area by vitrectomy followed by ablating the retinal with endolaser therapy. The vitreous cavity was filled with air at the end of the procedure. Vitrectomy was not performed on the infant's right eye due to poor prognosis. Upon examination under anesthesia (EUA) after surgery, the retina was found reattached with no vitreous hemorrhage, and intraocular pressure (IOP) measurement was 7 mm Hg. Postoperatively, a visual acuity test was performed using Cardiff Acuity Cards and revealed 6/60 on both eyes.




Figure 3. Fundus photo of the

A follow-up EUA was conducted, describing an IOP of 16 mmHg on both eyes, an axial length of 15.49

mm on the right, and 20.48 mm on the left. Moreover, it revealed that recurrent detachment did not occur on the left eye with the refraction test result on the left eye was S-3.75 C-5.75 x 85° and an undetermined result on the right eye due to opacity in the visual axis.

DISCUSSION

Surgical management is required for advanced stage ROP.⁹ The choice of surgical technique depends on the ROP stage, with the best visual outcome achieved when it is done at stage 4A ROP.⁹ Several procedures, including vitrectomy and scleral buckling, have been used to treat advanced-stage ROP.⁷ However, the anatomical and functional outcome of vitrectomy are more favorable than scleral buckling in stage 4 ROP.⁷ Since in the scleral buckle technique, there is a secondary procedure to remove the encircling element and leads to compression of anterior segment structure, which induces severe myopia. Therefore, vitrectomy is preferred as a treatment of choice for stage 4 ROP.⁷ Surgical outcomes for stage 5 ROP are mainly poor, with an anatomic success rate was 13%.^{8,10} In our case, vitrectomy with endolaser was performed to treat stage 4B ROP on the left eye. The endolaser procedure was intended to manage vascular activity. The same procedure was not implemented for the right eye with stage 5 ROP due to poor prognosis.

Kusuka, S. study reported that mean visual acuity postoperatively in stage 4A ROP ranges from 20/500 to 20/58 and for stage 4B ROP ranges from 20/1600 to 20/200.¹⁰ In this case, visual acuity was improved from the absence of blinking reflect in the first visit to 6/60 in both eyes after surgery. Furthermore, the refraction test was conducted using autorefraction with S-3.75 C-5.75 x 85° as the left eye result and undetermined result in the right eye due to opacity in the visual axis.

In Choi et al. study, the mean follow-up period of 5.6 years was conducted in the advanced stage of ROP with the vitrectomy procedure.⁸ It described that visual acuity measurement was required in followed up due to the possibility of unfavorable outcomes despite achieving retinal reattachment.⁸ Myopic outcomes after vitrectomy, as described in our case, commonly occur. Apart from myopia, other intra- and post-operative risks associated with ROP surgery include iatrogenic retinal breakage, vitreous hemorrhage, glaucoma, and cataracts¹⁰ which was observed to occur in a study with an average follow-up of 2.2 years.⁶ Notably, none of these risks were found on follow-up time in our study. A study by Xu et al. that described surgical outcomes in stage 4 ROP patients who underwent vitrectomy also described no observed complications such as uveitis, ocular hypertension, endophthalmitis, or any ocular or systemic adverse events in any of the patients with a follow-up of 12-36 months.¹¹ Therefore, we recommend that periodical follow-up for the next 5 years after surgery is required to detect refraction error, retinal reattachment, and further complications that may occur.

CONCLUSION

The functional outcome of vitrectomy surgery may not equate to anatomical success. Retinal reattachment and moderate visual outcome were

achieved by performing vitrectomy and endolaser in this case. Followed-up periodically is necessary for advanced stage ROP postoperatively.

REFERENCES

1. Azad R, Gilbert C, Gangwe A, Zhao P, Wu W, Sarbajna P et al. Retinopathy of Prematurity: How to Prevent the Third Epidemics in Developing Countries. *Asia-Pacific Journal of Ophthalmology*. 2020;9(5):440-448.
2. Blencowe H, Lawn J, Vazquez T, Fielder A, Gilbert C. Preterm-associated visual impairment and estimates of retinopathy of prematurity at regional and global levels for 2010. *Pediatric Research*. 2013;74(S1):35-49.
3. Siswanto J, Bos A, Dijk P, Rohsiswatmo R, Irawan G, Sulistijono E et al. Multicentre survey of retinopathy of prematurity in Indonesia. *BMJ Paediatrics Open*. 2021;5(1):e000761.
4. Tasman W. Revised Indications For The Treatment Of Retinopathy Of Prematurity Results Of The Early Treatment For Retinopathy Of Prematurity Randomized Trial. *Evidence-Based Eye Care*. 2004;5(3):156-157.
5. Bhende P, Gopal L, Sharma T, Verma A, Biswas R. Functional and anatomical outcomes after primary lens-sparing pars plana vitrectomy for Stage 4 retinopathy of prematurity. *Indian Journal of Ophthalmology*. 2009;57(4):267.
6. Yu Y, Kim S, Kim S, Choung H, Park G, Heo J. Lens-sparing Vitrectomy for Stage 4 and Stage 5 Retinopathy of Prematurity. *Korean Journal of Ophthalmology*. 2006;20(2):113.

7. Ramak R, Reza K, Mohammad R, Fariba G, Mehdi N. Surgical Management in Advanced Stages of Retinopathy of Prematurity; Our Experience. *Journal Of Ophthalmic And Vision Research*. 2009;4(3):185-190.
8. Choi J, Kim J, Kim S, Yu Y. Long-Term Results of Lens-Sparing Vitrectomy for Stages 4B and 5 Retinopathy of Prematurity. *Korean Journal of Ophthalmology*. 2011;25(5):305.
9. Shah P. Retinopathy of prematurity: Past, present and future. *World Journal of Clinical Pediatrics*. 2016;5(1):35.
10. Kusaka S. Current concepts and techniques of vitrectomy for retinopathy of prematurity. *Taiwan Journal of Ophthalmology*. 2018;8(4):216.
11. Xu Y, Zhang Q, Kang X, Zhu Y, Li J, Chen Y, et al. Early vitreoretinal surgery on vascularly active stage 4 retinopathy of prematurity through the preoperative intravitreal bevacizumab injection. *Acta Ophthalmologica*. 2013;91(4):e304-e10.



This work licensed under Creative Commons Attribution