

## THE ASSOCIATION BETWEEN DURATION OF SILICONE OIL TAMPONADE AND RETINAL REDETACHMENT AFTER SILICONE OIL REMOVAL: A SYSTEMATIC REVIEW AND META-ANALYSIS

Andi Arus Victor<sup>1</sup>, Enzo Sapuandi<sup>2</sup>, Raymond Pranata<sup>3</sup>

<sup>1</sup>Ophthalmology Department, Faculty of Medicine Universitas Indonesia-Dr Cipto Mangunkusumo Hospital, Jakarta, Indonesia

<sup>2</sup>Faculty of Medicine Universitas, Jakarta, Indonesia

<sup>3</sup>Faculty of Medicine, Universitas Pelita Harapan, Tangerang, Indonesia

### ABSTRACT

**Background:** Silicone oil (SO) removal following vitrectomy and injection of silicone oil may cause retinal redetachments (re-RD), with duration of tamponade being considered as the risk factor. So, we wanted to evaluate the duration of silicone oil tamponade as a risk factor of retinal redetachments after silicone oil removal.

**Result:** Ten studies comprising of 2120 eyes were included in this review. Pooled analysis showed no statistically significant difference between the re-RD group and the non-re-RD group in terms of SO duration (mean difference -1.87 months; 95% CI, -3.87 to 0.13;  $p=0.07$ ;  $I^2=53.1\%$ ). The re-RD rate did not differ between the shorter and longer duration of SO tamponade ( $OR=1.44$ ; 95% CI, 0.54 to 3.82;  $p=0.47$ ;  $I^2=63.3\%$ ).

**Conclusion:** The duration of SO tamponade was not associated with re-RD after SO removal.

**Keywords:** silicone oil, silicon oil tamponade, silicon oil removal, retinal detachment

**Cite This Article:** VICTOR, Andi Arus; SAPUANDI, Enzo; PRANATA, Raymond. THE ASSOCIATION BETWEEN DURATION OF SILICONE OIL TAMPONADE AND RETINAL REDETACHMENT AFTER SILICONE OIL REMOVAL: A SYSTEMATIC REVIEW AND META-ANALYSIS. International Journal of Retina, [S.l.], v. 5, n. 1, p. 32, feb. 2022. ISSN 2614-8536. Available at: <<https://www.ijretina.com/index.php/ijretina/article/view/183>>. doi: <https://doi.org/10.35479/ijretina.2022.vol005.iss001.183>

### INTRODUCTION

\*Correspondence to:

Andi Arus Victor,  
Universitas Indonesia, Cipto  
Mangunkusumo Hospital,  
arvimadao@yahoo.com

Management of retinal detachment (RD) with vitrectomy with silicone oil (SO) tamponade has become more popular due to its effectiveness in treating complicated retinal detachments, including proliferative vitreoretinopathy (PVR), giant retinal tears, and traumatic RD and has improved the prognosis.<sup>1</sup> Prolonged tamponade can lead to several complications, such as secondary glaucoma, endothelial decompensation, cataract, and keratopathy.<sup>2</sup> Therefore, silicone oil removal (SOR) should be done after a certain period of time when

the retinal condition has been stabilized. However, many studies also found problems, which retinal redetachment (re-RD) has been one of the most common events occurred due to lack of oil-supporting effect and the proliferation of epiretinal membranes after SOR. Duration of silicone oil tamponade has been considered as one of the risk factors of re-RD after SOR, yet the association between them is still uncertain. Therefore, we conducted a systematic review and meta-analysis to summarize the data from the including studies to find out the retinal attachment outcome based on the silicone oil tamponade duration.

## METHOD

### Search Strategy and Study Selection

This is a systematic review and meta-analysis which followed Preferred Reporting Items for Systematic Review and Meta-Analysis (PRISMA) 2015 guideline. We conducted a literature search up until 19 March 2020 from several databases, such as PubMed, Scopus, the Cochrane Library, and Science Direct to gather studies related to the PICO, with the following search terms: "retinal detachment," "silicone oil," "duration," and

"redetachment." The eligibility criteria for this study were: (1) the usage of silicone oil tamponade in patients with retinal detachment; (2) studies concerning silicone oil tamponade duration related to re-RD after SOR; (3) comparative studies with the study design of randomized controlled trials, cohort studies, or case-control studies; (4) rate ratio values reported with 95% confidence interval (CI) or data available to be calculated. We excluded studies written other in English, animal studies, and nonpublished materials. The flow diagram of study selection showed in Figure 1.

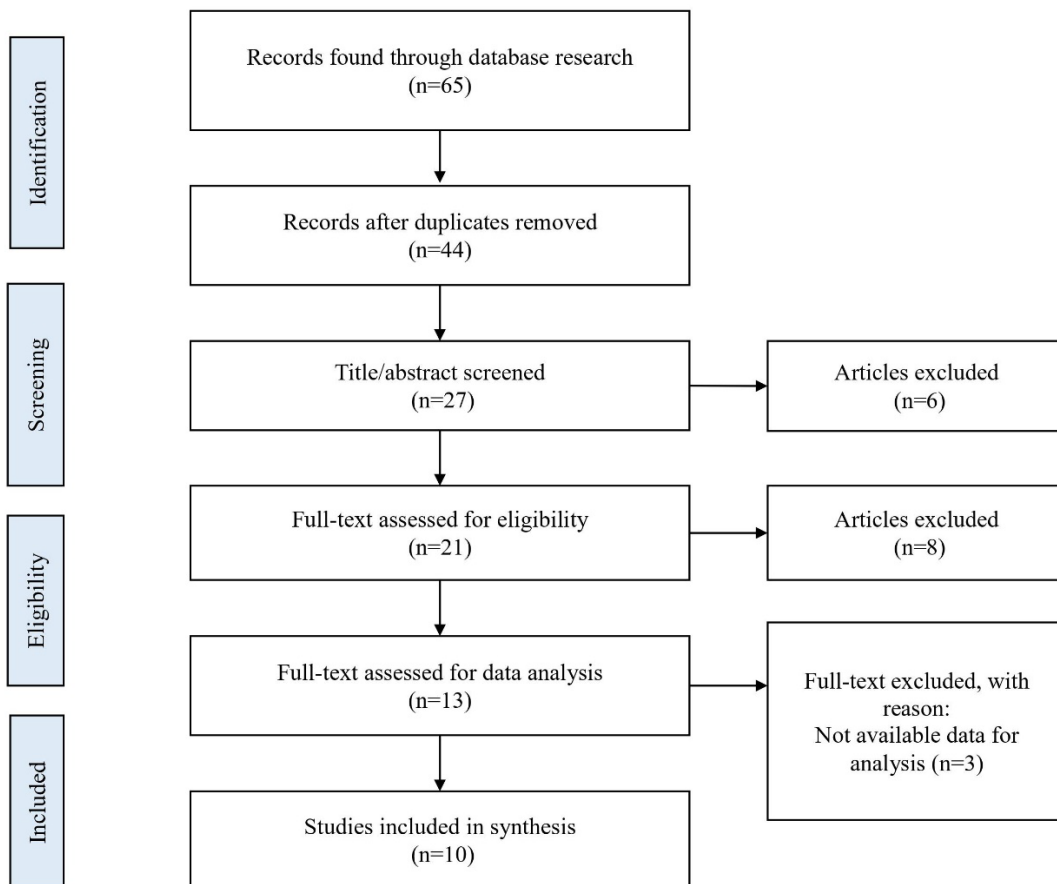


Figure 1. **Flow diagram study selection**

### Data Extraction and Study Quality Assessment

Data were screened and extracted, and the following data from studies included for synthesis were collected: author, study design, setting, sample size, subject characteristic, outcome, and risk factor of RD. We evaluated the level of evidence by using Oxford Centre for Evidence-Based Medicine and assessed the risk of bias using Newcastle-Ottawa Scale for unrandomized controlled studies. Studies regarded as high quality if it scored seven or more stars in total. Four studies scored eight stars and six studies scored seven stars. For the selection of the study, most of the study did not mention its representativeness of exposed cohort, while others just from one institution. The comparability was slightly different, with four studies mentioned a minimum follow-up duration. The outcome of studies was all scored one star for respective component.

### Statistics Analysis

The meta-analysis was conducted using STATA 16 (Stata Corp, TX). For the heterogeneity test, we used the Chi-squared test based on Cochran's Q and  $I^2$  statistics. There were seven studies which divided patients into groups with re-RD and no re-RD presented with its respective mean duration of tamponade in months; and four studies which divided patients based on the duration of tamponade (shorter and longer duration) with its respective cut-off and rate of redetachment. Therefore, the statistical analysis was divided into two methods with different effect estimates. The first group of studies was analyzed for pooled mean differences. The second group of studies was analyzed for odds ratio. Restricted-maximum likelihood (REML) random-effects meta-analysis was performed regardless of heterogeneity. The pooled effect was determined with  $p < 0.05$  was considered statistically significant.

### Results

We identified 10 studies with a total of 2,160 eyes in this systematic review and meta-analysis. The studies began at 1989 and ended at December 2017. All the studies were retrospective review with consecutive sampling. The review of each studies explained in Table 1. Three studies included patients underwent pars plana vitrectomy (PPV) and silicone oil (SO) tamponade, followed by silicone oil removal (SOR), while seven studies included patients underwent SOR, despite its initial treatment. Most of the studies did not only analyze the duration of silicone oil tamponade, but also other risk factors contributing the incidence of retinal detachment in the population. Statistically significant risk factors showed in the studies were the frequency of retinal detachment<sup>3</sup>, myopic patients<sup>3</sup>, visible remnants of the vitreous base<sup>3,4</sup>, surgeon performed the PPV<sup>3</sup>, number of retinal surgeries performed before PPV with SO tamponade<sup>3,10,11</sup>, frequency RAPD,<sup>3</sup> vitreous hemorrhage in the first 3 days until 1 week after SOR<sup>3,4</sup>, longer time between the onset of symptoms and the SO application<sup>4</sup>, worse preoperative visual acuity (VA)<sup>4,5,7,11</sup>, rhegmatogenous retinal detachment as the etiology<sup>4</sup>, female patients<sup>7</sup>, presence of rubeosis periooperative<sup>7</sup>, PDR pre-SOR<sup>7</sup>, presence of encircling band<sup>10</sup>, cumulative retinectomy size  $> 180^\circ$ <sup>10</sup>, age  $\geq 70$ <sup>10</sup>, giant tear as indication of SO injection<sup>10</sup>, PVR stage above A+B<sup>11</sup>, presence of replications<sup>11</sup>, and aphakic eyes<sup>11</sup>. Nine studies showed that duration of oil tamponade was not a statistically significant risk factor of retinal redetachment. Only Scholda s showed the significant result, with  $p < 0.02$ , which redetachment happened more in shorter duration group.

Six studies presented the result by showing mean duration of silicone oil tamponade for both groups, patients with and without retinal detachment (Table 2), while three studies presented by dividing patients with retinal detachment into two groups based on the duration of tamponade (Table 3). Only one study analyzed the result with two approaches, but did not show the raw data of redetachment cases in both groups of SO tamponade duration (Table 3).<sup>8</sup> From all the studies, only study by Scholda and Tan had a significant result statistically, with  $p < 0.02$  and  $p = 0.009$ , respectively.

Meta-analysis was conducted to find out whether duration of SO tamponade can affect the rate of redetachment after SOR. Six studies provided mean and standard deviation of duration of SO tamponade data between the re-RD group and the non-re-RD group (considered as control group).<sup>3-5,8,9,11,12</sup> Pooled analysis showed no statistically

significant difference between the re-RD group and the non-re-RD group in terms of SO duration (mean difference -1.87 months; 95% CI, -3.87 to 0.13;  $p = 0.07$ ;  $I^2 = 53.1\%$ ;  $P = 0.05$ ) [Figure 2].

Four studies concentrated in showing the case of re-RD between groups with shorter and longer duration. However, each study used a different cut-off for its group. Goezinne and Flakner divided groups into  $< 6$  and  $\geq 6$  months<sup>7,8</sup>, La Heij  $\leq 6$  and  $> 6$  months<sup>10</sup>, and Tan  $< 2$  and  $\geq 2$  months duration<sup>6</sup>. We could not further analyze Flakner's study because it did not provide any raw data regarding the number of re-RD case, with only showing insignificant result of P value.<sup>8</sup> A meta-analysis from three studies<sup>6,7,10</sup> indicates that the re-RD rate did not differ between the shorter and longer duration of SO tamponade (OR=1.44; 95% CI, 0.54 to 3.82;  $p = 0.47$ ;  $I^2: 63.3\%$ ,  $p = 0.07$ ) [Figure 3].

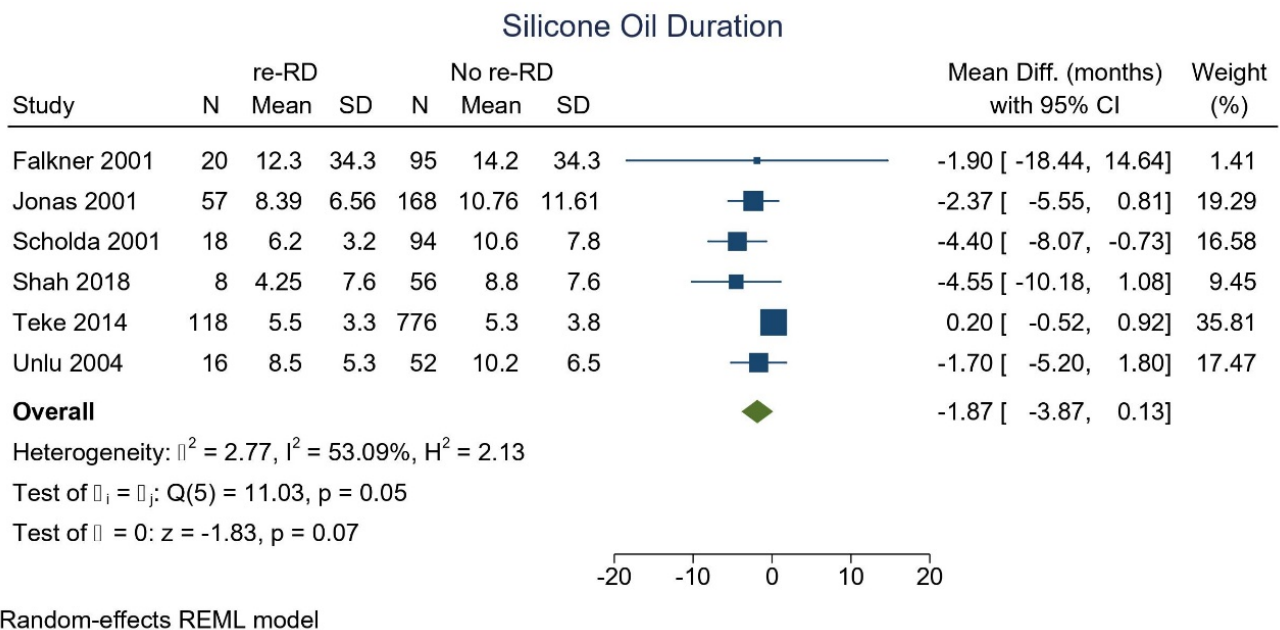


Figure 2. Forest plot, mean difference and 95% confidence interval (CI) of silicone oil tamponade duration for retinal redetachment after silicone oil removal

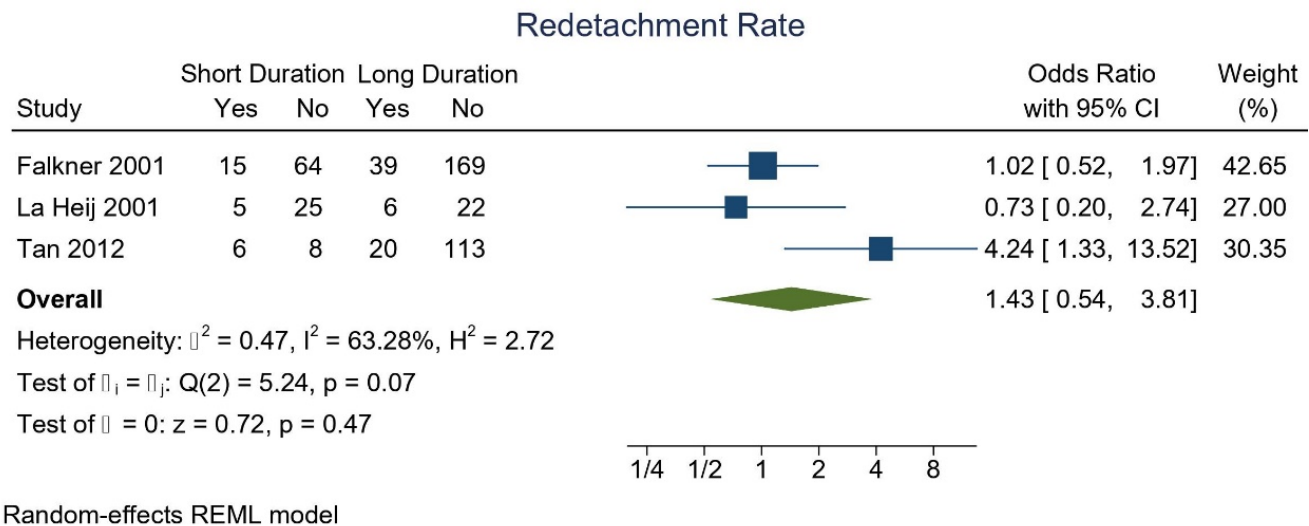


Figure 3. Forest plot, odds ratio and 95% confidence interval (CI) of shorter dan longer duration group for case of retinal detachment after silicone oil removal

## DISCUSSION

Silicone oil injection following vitrectomy is a promising therapeutic option for complicated retinal detachment cases. However, there were many complications reported due to prolonged tamponade, such as secondary glaucoma, cataract, endothelial decompensation, emulsification, and keratopathy; thus, its usage was temporary and needs to be removed once the retina was completely attached.<sup>2,13</sup> After SOR, re-RD occurred as a major complication, as it was stated in The Silicone Study Group Report 6, which found that SOR increases the chance of re-RD.<sup>14</sup> The proposed mechanism of re-RD after SOR were redetached of preexisting breaks that were previously tamponade using SO due to insufficient retinopexy, establishment of new breaks, or residual traction. Re-RD after SOR was commonly occurred within six months after SOR, especially during the first 50 days.<sup>15</sup> Redetachment rates may vary, starting from 9% to over 25%, and sometimes reaching 66%.<sup>16</sup>

Many studies focused on presenting the possible risk factors and protective factors of re-RD after SOR. One of the factors that was still uncertain, which vary among the studies' result, was the duration of SO tamponade. There was no exact time period of tamponade before its removal, so the decision was entirely according to the discretion of vitreoretinal surgeon.<sup>16</sup> The timing of SOR removal in the studies included was starting from less than 1 month up to 96 months. The decision to perform SOR strongly depended on the anatomical and functional outcome, and/or the occurrence of intraocular inflammation for the respective patients' eye; which explained the various mean and wide standard deviation in one study compared to each other.<sup>17</sup> However, some literatures recommended to remove silicone oil after 3-12 months.<sup>18</sup> The anatomical success rate after 6 months of SOR was similar for patients with 4-12 months, 14-18 months, >18 months SO tamponade, ranging from 84-88%.<sup>19</sup> It was more or less in line with the anatomical outcomes of retina attachment duration, which reached stability after 6-24 months of SO. Therefore, early SOR <3 months was reported to experience higher risk of redetachment.

Azen reported the highest percentage of re-RD was the patients with SOR after 0-3 months and the lowest was after 7-12 months.<sup>20</sup>

However, study conducted by Morphis et al showed complications of long-term SO tamponade, such as corneal complications (band keratopathy and decompensation), iris rubeosis, post synechiae, optic neuropathy and increased intraocular pressure (IOP), proliferative retinopathy, emulsification, and migration of oil. The majority of these patients had either recurrent vitreous hemorrhage in the case of patients with proliferative diabetic retinopathy (PDR) or re-RD.<sup>21</sup> There were also several studies showing the risk factor of re-RD, such as aphakic eye, high myopia, previous failed retinal surgery, SO tamponade due to ocular trauma, PDR and PVR, rubeosis, abnormal IOP, and emulsified oil.<sup>22</sup> Al-Wadani stated that the cause of re-RD in the study was the development of severe posterior PVR.<sup>23</sup> Based on this statement, we can conclude that the longer duration of SO tamponade can cause complications, which further acted as the risk factors of re-RD.

Our meta-analysis did not support the notion that re-RD cases had a significant longer SO tamponade duration. Possible cause of heterogeneity can be explored through meta-regression analysis, unfortunately, there were less than 10 studies and they did not report possible confounders uniformly, thus lacking data to perform adequately powered meta-regression.

Due to the results stated above, further study for more reliable and accurate findings is needed. The limitation of this study are all the studies included were retrospective review, with different sample population, ranging from around sixty to eight hundred, which can affect the outcome. The inclusion criteria were only patients underwent SOR with certain period of minimum follow-up,

where included patients had a wide range of pathologies. To further analyze the impact of duration of SO tamponade towards re-RD, it is suggested to conduct a multivariate analysis.

## CONCLUSION

The duration of SO tamponade was not associated with re-RD after SO removal.

## REFERENCES

1. Antoun J, Azar G, Jabbour E, Kourie HR, Slim E, Shackal A, et al. Vitreoretinal surgery with silicone oil tamponade in primary uncomplicated rhegmatogenous retinal detachment. *Retina* 2016;0(0):1-7.
2. Moisseiev J, Barak A, Manaim T, Treister G. Removal of silicone oil in the management of glaucoma in eyes with emulsified silicone. *Retina*. 1993;13(4):290-295.
3. Jonas BJ, Knorr HLJ, Rank RM, Budde WM. Retinal detachment after removal of intraocular silicone oil tamponade. *Br J Ophthalmol* 2001;85:1203-7.
4. Teke MY, Balikoglu-Yilmaz M, Yuksekkaya, Citirik M, Elgin U, Kose T, et al. Surgical outcomes and incidence of retinal detachment in cases with complicated retinal detachment after silicone oil removal. *Retina* 2014;34(10):1926-38.
5. Unlu N, Kacaoglan H, Acar MA, Sargin M, Aslan BS, Duman S. Outcome of complex retinal detachment surgery after silicone oil removal. *Int Ophthalmol* 2004;25:33-6.
6. Tan HS, Dell'Omo R, Mura M. Silicone oil removal after rhegmatogenous retinal detachment: comparing techniques. *Eye* 2012;26:444-7.
7. Goezinne F, La Heij EC, Berendschot TTJM, Liem ATA, Hendrikse F. Risk factors for redetachment and worse visual outcome after silicone oil removal in eyes with complicated retinal detachment. *Eur J Ophthalmol* 2007;17:627-37.
8. Falkner CI, Binder S, Kruger A. Outcome after silicone oil removal. *Br J ophthalmol* 2001;85:1324-7



9. Choudhary MM, Choudhary MM, Saeed MU, Ali A. Removal of silicone oil. *Retina* 2012;32(10):2034-8.
10. La Heij EC, Hendrikse F, Kessels AGH. Results and complications of temporary silicone oil tamponade in patients with complicated retinal detachments. *Retina* 2001;21(2):107-14.
11. Scholda C, Egger S, Lakits A, Walch K, von Eckardstein E, Biowski R. Retinal detachment after silicone oil removal. *Acta Ophthalmol Scand* 2000;78:182-6.
12. Shah R, Byanju R, Pradhan S. Outcomes of silicone oil removal in complex retinal detachment. *Nepal J Ophthalmol* 2018;10(20):124-9.
13. Casswell AG, Gregor ZJ. Silicone oil removal. I. The effect on the complications of silicone oil. *Br J Ophthalmol*. 1987;71(12):893-897.
14. Hutton WL, Azen SP, Blumenkranz MS, et al. The effects of silicone oil removal. Silicone Study Report 6. *Arch Ophthalmol* 1994; 112: 778-85.
15. Abu El-Asrar AM, Al-Bishi SM, Kangave D. Outcome of temporary silicone oil tamponade in complex rhegmatogenous retinal detachment. *Eur J Ophthalmol* 2003;13:474-81.
16. Stappler T, Morphis G, Irigoyen C, Heimann H. Is there a role for long-term silicone oil tamponade for more than twelve months in vitreoretinal surgery? *Ophthalmologica* 2011;226(suppl 1):36-41.
17. Schwarzer H, Mazinani B, Plange N, Fuest M, Walter P, Roessler G. Clinical observations and occurrence of complications following heavy silicone oil surgery. *BioMed Research Intl* 2014. doi:10.115/2014/706809
18. Moisseiev E, Ohana O, Gershovitch L, Barak A. Visual prognosis and complications following silicone oil removal. *Eur J Ophthalmol* 2013;23(2):236-41.
19. Halberstadt M, Domig D, Kodjikian L, Koerner F, Garweg JG. PVR recurrence and the timing of silicone oil removal. *Klin Monatsbl Augenheilkd* 2006;223:361-6.
20. Azen SP, Scott IU, Flynn HW, Lai M, Topping TM, Benati L, et al. Silicone oil in the repair of complex retinal detachment. *Ophthalmology* 1998;105:1587-97.
21. Morphis G, Irigoyen C, Eleuteri A, Stappler T, Pearce I, Heimann H. Retrospective review of 50 eyes with long-term silicone oil tamponade for more than 12 months. *Graefes Arch Clin Exp Ophthalmol* 2012;250:645-52.
22. He Y, Zeng S, Zhang Y, Zhang J. Risk factors for retinal redetachment after silicone oil removal: a systematic review and meta-analysis. *Ophthalmic Surg Lasers Imaging Retina* 2018;49:416-24.
23. Al-Wadani SF, Abouammoh MA, El-Asrar AMA. Visual and anatomical outcomes after silicone oil removal in patients with complex retinal detachment. *Int Ophthalmol* 2014;34:549-56.



This work licensed under Creative Commons Attribution