

RESOLUTION OF RETINAL BLEEDING AND EXUDATIVE RETINAL DETACHMENT AFTER CHEMOTHERAPY WITH MELPHALAN IN MULTIPLE MYELOMA

Ari Andayani¹, I Putu Budhiastra¹, I Wayan Losen Adnyana², Made Paramita Wijayati¹

¹Department of Ophthalmology, Udayana University, Sanglah Hospital Bali

²Internal Medicine Department, Udayana University, Sanglah Hospital Bali

ABSTRACT

Introduction: Multiple myeloma is the second most common hematologic cancer. It is characterized by the clonal proliferation of malignant plasma cells and associated organ dysfunction. Ophthalmic manifestations include hyperviscosity retinopathy and retinal detachment. The aim of this study is to report retinal manifestation in Multiple Myeloma.

Methods: A man 45 years old, complained loss of vision on both eyes especially left eye over 1 month. He also feels weakness and 3 times spontaneous nose bleeding. His visual acuity is 6/12 on the right and 2/60 left eye with Retinal Bleeding and Retinal Detachment. His Laboratory examination result increase in WBC $65.91 \times 10^3/\mu\text{L}$ (Neutrophil, Monocyte, Basophil and Lymphocyte) decrease RBC $3 \times 10^6/\mu\text{L}$, HGB 6.85 g/dL, normal PLT $193.60 \times 10^3/\mu\text{L}$, Normal Bleeding and Clotting Time and increase ESR 140 mm/hour. Multiple myeloma was diagnosed by Internal Department with bone marrow biopsy and increase of Gamma Globulin.

Results: The patient was treated with melphalan 3 tablet 2 times a day and prednisone 4 mg 3 times a day for 5 days every 28 days. After 8 month the VA 6/6 on the right and 6/10 on the left with complete resolution of on the right eye and there are resolution on the left eye with fibrosis, the laboratory examination normal WBC $3.8 \times 10^3/\mu\text{L}$ with Neutrophil 59.3%, Monocyte 6.1 %, Eosinophil 6.3 %, Basophil 0.3 % and Lymphocyte 28.0 %, normal RBC $4.6 \times 10^6/\mu\text{L}$, slightly decrease HGB 12.8 g/dL, normal PLT $177.0 \times 10^3/\mu\text{L}$ and decrease Gamma Globulin.

Discussion: This case of bilateral Retinal Bleeding and Exudative Retinal Detachment are remarkable for both its presentation and response to melphalan therapy. Treatment with melphalan and prednisone alone was sufficient to clear the Retinal Bleeding and restoration of Exudative Retinal Detachment.

Conclusion: Complication of Multiple Myeloma can caused organ dysfunction such as retinal bleeding and exudative retinal detachment. Early Diagnosis is very crucial. In our case combination chemotherapy with Melphalan and Prednisone showed clinically significant resolution. Workshop Internal Department and Ophthalmology Department are very important for management and monitoring ophthalmology manifestation in multiple myeloma.

Keywords: Multiple Myeloma, Retinal Bleeding, Exudative Retinal Detachment, Melphalan Chemoteraphy.

Cite This Article: ANDAYANI, Ari et al. Resolution of Retinal Bleeding and Exudative Retinal Detachment After Chemotherapy with Melphalan In Multiple Myeloma. International Journal of Retina, [S.l.], v. 1, n. 1, sep. 2017. ISSN 2614-8536. Available at: <https://www.ijretina.com/index.php/ijretina/article/view/10>

INTRODUCTION

Multiple myeloma is the second most associated organ dysfunction.¹ Multiple common hematologic cancer. It is characterized Myeloma usually occurs between 40 and 70 by the clonal proliferation of malignant plasma years of age.² Multiple myeloma occurs slightly cells in the bone marrow microenvironment, more frequently in men than in women (1.6:1).^{3,4} monoclonal protein in the blood or urine, and

*Correspondence to:
Ari Andayani,
Department of
Ophthalmology,
Universitas Udayana,
akoe.arie35@gmail.com

Nearly 74,800 Americans currently have MM, and an estimated 10,700 will die from the disease in 2012.⁵

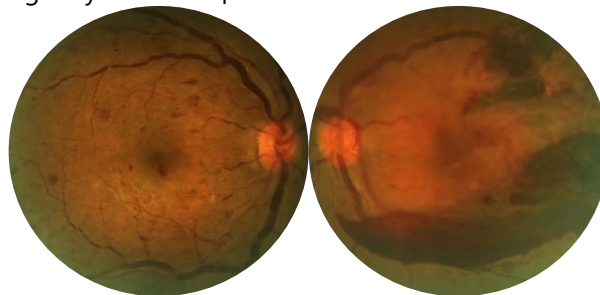
Multiple Myeloma accompanied by nonspecific symptoms such as generalized fatigue, weight loss, and bone pain on movement. Osteolytic lesions and pathological fractures may be seen on skeletal survey.² Multiple Myeloma can cause many complications, including Calcium elevation (hypercalcemia), Renal (kidney) dysfunction, Anemia and Bone disease. This constellation of signs and symptoms is commonly referred to as "CRAB".⁵ Multiple Myeloma can present as pathology in practically all the orbital and ocular tissues. Early identification and early treatment is necessary to prevent irreversible visual loss. Ophthalmic manifestation in multiple myeloma is rare. Retinal vascular disorders have been reported in up to 66% of patients with multiple myeloma. Retinal features of hyper viscosity include venous dilatation, segmentation and tortuosity, superficial and deep hemorrhages and detachment of both the sensory retina and retinal pigment epithelium.⁶ The two pathophysiological processes that give rise to a majority of the ophthalmic signs are tissue infiltration by plasma cells and hematological abnormalities.² Laboratory tests characteristically reveal a normocytic normochromic anemia, raised erythrocyte sedimentation rate, hypercalcemia, renal dysfunction, Bence Jones proteinuria and monoclonal globulin spike on serum electrophoresis. Bone marrow biopsy usually confirms the diagnosis by showing an uncontrolled proliferation of plasma cells.^{2,7,8}

There is no one standard treatment for MM, and choice of therapy depends on many factors, including physical exam and laboratory test results, the specific stage or classification of the disease, age and general health, symptoms, presence of complications and prior treatment. Commonly used regimens for initial therapy include traditional agents such as corticosteroids (e.g., dexamethasone) and alkylating agents such as melphalan.⁵

METHOD

This is about a case report. A man 45-year-old, complained loss of vision on both eyes especially left eye over 1 month. He also feels weakness and 2 times spontaneous nose bleeding. His visual acuity is 6/12 on the right and 2/60 left eye. Anterior Segment examination in normal limit. Dilated Fundus examination showed dilatation and tortuosity vein (sausage shape) with dot, blot, flame shape, roth spot and decrease macular reflex on the right eye. We found vitreous hemorrhage with

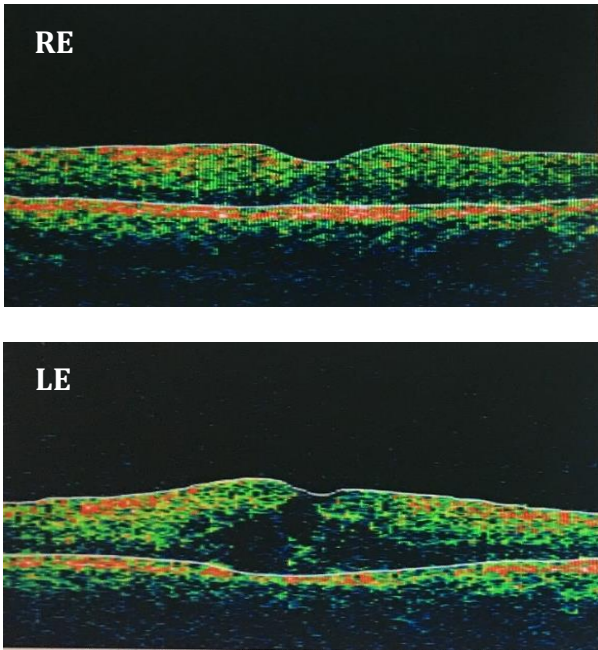
dilatation and tortuosity vein (sausage shape), subhyaloid bleeding and decrease macular reflex on the left eye. Ocular Computed Tomography was done and showed increase in Central Retinal Thickness (CRT) 317 μ m on the right eye and 482 μ m on the left.



Picture 1. Fundus Photo when first came show Retinal bleeding, Venous dilatation and tortuosity on both eye (Courtesy by VR Division)

We diagnosed patient with Retinal Bleeding and Eksudatif Retinal Detachment and Vitreous Hemorrhage on the left eye. His Laboratory examination result RBC $3.25 \times 10^6/\mu\text{L}$ (4.4-5.9), Hemoglobin 7.8 g/dL(13.2-17.3), Hematocrit 26% (40-52), MCV 80 fL (80-100), MCH 24 pg (26-34), MCHC 30 g/dL(32-36), PLT $171 \times 10^3/\mu\text{L}$ (150-440), WBC $8.7 \times 10^3/\mu\text{L}$ (3.8-10.6) , Basophil 0.3% (0-1) Absolut $0.03 \times 10^3/\mu\text{L}$, Eosinophil 4.4% (2-4) Absolut $0.38 \times 10^3/\mu\text{L}$, Neutrophil 43.2% (50-70) Absolut $3.74 \times 10^3/\mu\text{L}$, Lymphocyte 45.2% (25-40) Absolut $3.92 \times 10^3/\mu\text{L}$, Monocyte 6.9% (2-8) Absolut $0.60 \times 10^3/\mu\text{L}$, ESR 140 mm/hour (0-15), BT 1.5 minute (1-6), CT 9.0 minute (5-15), PT 24.2 second (10.8-14.4), APTT 43.2 second (26.4-37.6), INR 2.4, SGOT 18 U/L (<33), SGPT 12 U/L (<50), Ureum 14 mg/dL (6-20), Creatinin (Cr) 1.18 mg/dL (0.7-1.2), Chlorida (Cl) 110 mmol/L (98-107), Natrium(Na) 137 mmol/L (136-145), Kalium (K) 4.1 mmol/L (3.5-5.1), IgM, IgG anti Toxoplasma and anti CMV were negative, IgM anti HSV1 was negatif, VDRL and TPHA were nonreactif, Fasting Blood Sugar 94 mg/dL (<100), 2hPP Blood Sugar 106 mg/dL (<140), Uric Acid 12.0 mg/dL (<7.0).

We consulted this patient to Internal department but unfortunately the patient came to emergency room with spontaneous nose bleeding on the next day. His Laboratory result increase in WBC $65.91 \times 10^3/\mu\text{L}$ (Neutrophil, Monocyte, Basophil and Lymphocyte) decrease RBC $3 \times 10^6/\mu\text{L}$, HGB 6.85g/dL, normal PLT $193.60 \times 10^3/\mu\text{m}$. The patient was consulted to Hemato Oncology and was planned to bone marrow aspiration with diagnosed suspect Acute Myeloid Leukemia.

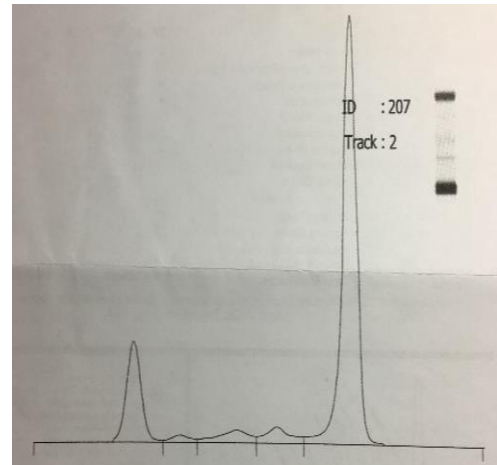


Picture 2. OCT Macula show increase Central Retinal Thickness (Courtesy by VR Division), RE =Right eye, LE= Left Eye

Patient was consulted to our division. On our examination we found visual acuity is 6/12 on the right and 5/60 left eye. Anterior Segment examination in normal limit. Dilated Fundus examination showed dilatation and tortuosity vein (sausage shape) with dot, blot, flame shape, Roth spot and decrease macular reflex on the right eye. We found decrease on vitreous hemorrhage with dilatation and tortuosity vein (sausage shape), subhyaloid bleeding and decrease macular reflex on the left eye. We planned to observation and waited for the bone marrow aspiration resulted.

Bone marrow aspiration was done 3 days after the patient was consulted to our division. The resulted are Multiple Myeloma with Hipercelluler, Erytroid Sytem Activity, Myeloid Sytem Activity, Megakaryocytes Sytem Activity decrease and 40 % Plasma Cell Infiltration. Electrophoresis and bone survey was planned.

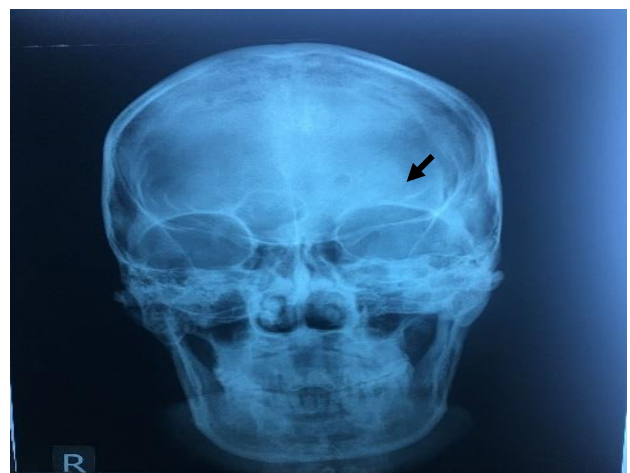We found increased in Gamma Globulin 8.62 g/dL (0.9-1.5), 71.8% (12.1-21.1) with total protein 12 g/dl. Bone Survey examination showed didapatkan Lytic soliter lesion on left frontal bone. Multiple Myeloma Stage IIIA was diagnosed by hemato-oncology division and the patient was given Melphalan 6 mg two times per day and prednisone 20 mg three time per day for 5 days and repeated for 28 days.



Picture 3. Electrophoresis Protein Serum showed increased in Gamma Globulin (black arrow) (Courtesy by Ophthalmology Department, 2017)

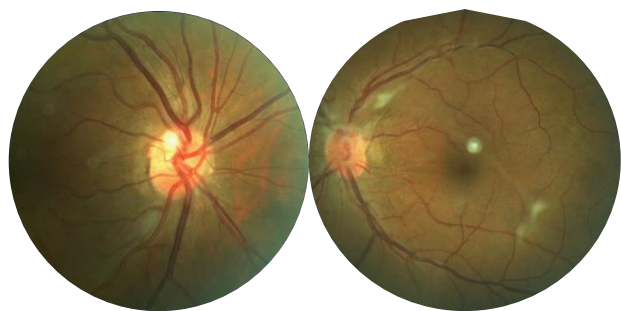
RESULT

After 10 cycles of melphalan therapy, patient came to eye polyclinic. On our examination we found visual acuity is 6/6 on the right eye and 6/10 with pinhole not improve on the left. Dilated funduscopy examination we found complete resolution on the right eye with no bleeding and tortuosity. Macular reflex are positive. On the left eye we found weiss ring and fibrosis in the vitreous, with no subhyaloid bleeding, but unfortunately the macular reflex still decreased.



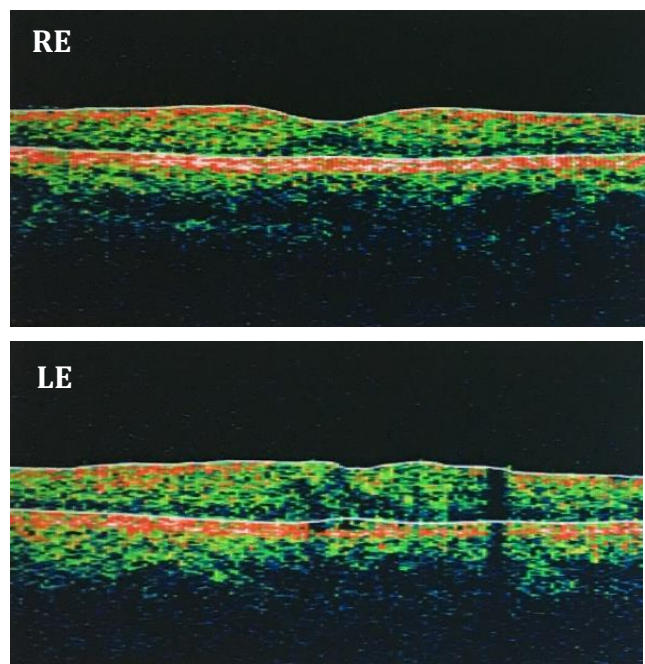
Picture 4. Lytic Lesson Soliter in Left Frontal (arrow) (Courtesy by Ophthalmology Division,2017)

We took fundus photograph and OCT to the patient and showed normal fundus image on the right eye and Weiss ring with fibrotic lesion on the left. Ocular Computed Tomography showed Central Retinal Thickness (CRT) on the right eye was normal (224 µm) and 324 µm on the left.



Picture 5. Fundus Photography. It shows Resolution on both eye, with Weiss ring and fibrosis vitreous in left eye (Courtesy by VR Division)

Laboratory examination results with RBC $4.6 \times 10^6/\mu\text{L}$ (4.5-5.9), Hemoglobin (Hb) 12.8 g/dL (13.5-17.5), Hematocrit 38.6 % (41-53), MCV 83.9 fL (80-100), MCH 27.8 pg (26-34), MCHC 33.2 g/dL(31-36), PLT $177.0 \times 10^3/\mu\text{L}$ (150-440), WBC $3.8 \times 10^3/\mu\text{L}$ (4.1-11), Basophil 0.3 % (0.0-2.0), Eosinophil 6.3 % (0.0-5.0), Neutrophil 53.9 % (47-80), Lymphocyte 28.0 % (13-40), Monocyte 6.1 % (2.0-11.0) and electrophoresis protein serum showed Gamma 2.96 g/dL (0.9-1.5), 38.4 % (12.1-21.1). Patient was diagnosed with retinal bleeding and exudative retinal detachment (resolution) with Posterior Vitreous Detachment (PVD) Complete on the left eye. Patient was giving Melphalan therapy from hemato Oncology division.



Picture 5. OCT Macula show resolution Central Retinal Thickness (Courtesy by VR Division)

DISCUSSION

Multiple myeloma is a hematologic malignancy caused by infiltration of bone marrow by bone marrow-derived

plasma cells followed by the production of monoclonal Ig by these cells. Symptomatic hyperviscosity is observed in 2%–6% of patients with multiple myeloma.^{9,10} Multiple myeloma is characterized by bone pain, skeletal punched out lesions, anemia, renal insufficiency, hypercalcemia, and increased susceptibility to infections. Ocular involvement with multiple myeloma can be found throughout the eye and visual pathways as well as the orbit, although rarely are these the presenting signs. Specifically, the retina may have dilated and tortuous veins, retinal hemorrhages, Roth spots, vitreous hemorrhages, cotton wool spots and exudates, and central and branch retinal vein occlusions. Uncommonly, retinal and choroidal detachments can be seen in multiple myeloma.^{9,11,12}

This case is unusual in that the initial presentation of the patient was significant decrease in visual acuity 6/12 on the right and 2/60 left eye. Posterior examination we found with roth spot and intraretinal bleeding with venous dilatation and tortuosity. Macula reflex decrease on the right and hazy (bleeding) on vitreous with subhyaloid bleeding, intraretinal bleeding, venous dilatation and tortuosity. Macula reflex decrease. OCT macula show CRT on RE 317 μm and LE 482 μm .

Retinal bleeding is caused by hyperviscosity syndrome of Multiple myeloma. The shear wall stress due to increased blood viscosity is greatest on vessels with the smallest cross-sectional area and highest flow rates, providing an explanation for localization of haemorrhage to the arteriolar beds. Retinal vein swelling and haemorrhage is probably secondary to compression of the central optic vein due to retinal artery engorgement as a result of increased viscosity.¹³ Exudative retinal detachment that happen in this case is unusual. Dogan et al speculate that Ig accumulation in the subretinal space increases the oncotic pressure, while fluid accumulation in the subretinal area separates the RPE from the photoreceptors.¹¹

Patient feel weakness and history of spontaneous nose bleeding was positive. Laboratory Examination show increase ESR 140 mm/hour, decrease HGB 6.85 g/dL. Renal Function in normal limit. Electrophoresis show increase in Gamma 8.62 g/dL (0.9-1.5), 71.8% (12.1-21.1). Skull AP Lateral on the bone survey showed Soliter Lytic Lesion in Left Frontal. Bone marrow aspiration result Plasma Cell Infiltration 40% leading to Multiple Myeloma

Multiple Myeloma is classified as asymptomatic or symptomatic, depending on the absence or presence related organ damage.¹ Laboratory tests characteristically reveal a normocytic normochromic anemia, raised ESR, hypercalcemia, renal dysfunction, Bence Jones proteinuria and monoclonal globulin spike on serum electrophoresis. Bone marrow biopsy confirms the diagnosis (uncontrolled proliferation of plasma cells).²

Our patient was diagnosed Multiple Myeloma Stage IIIA by hemato-oncology division and the patient was given Melphalan 6 mg two times per day and prednisone 20 mg three time per day for 5 days and repeated for 28 days.

Since the 1960s, melphalan and steroid have been the standard of therapy. Chemotherapy consisted of oral melphalan (8 mg/m) on days1–4 and oral dexamethasone (40 mg/day) on days 1–4 and days 9–12. The cycles were repeated every 28 days for a total of 12 cycles or until intolerance or disease progression was observed.^{13,14}

This case of bilateral retinal bleeding and exudative retinal detachment are remarkable for both its presentation and response to therapy. Our case is also remarkable in that there was a favorable response to therapy by way of visual acuity improvement, resolution on retinal bleeding and exudative retinal detachment after 10 cycles therapy with melphalan and prednisone although there is PVD complete and fibrosis after vitreous hemorrhage on the left eye.

CONCLUSION

Complication of Multiple Myeloma can caused organ disfunction such as retinal bleeding and exudative retinal detachment. Early Diagnosis is very crucial. In our case combination cemotherapy with Melphalan and Prednison showed clinically significant resolution. Workshop Internal Department and Ophthalmology Department are very important for management and monitoring ophthalmology manifestation in multiple myeloma.

ACKNOWLEDGMENT: thanks to dr I Wayan Losen Adnyana Consultant Hemato Oncology that help to confirm the diagnosis and do bone marrow aspiration quickly.

REFERENCES

1. Vasquez FJ, Sobenko N, Schutz N, Altszul M, Lagruta I, Mateos MV, Fantl D. Acute Loss of Vision as the Intial Symptom of Multiple Myeloma. *Clinical Lymphoma, Myeloma & Leukemia*. 2012; 12(2): 148-150.
2. Fung S, Selva D, Leibovitch I, Hsuan J, Crompton J. Ophthalmic Manifestations of Multiple Myeloma. *Ophthalmologica*. 2005;219:43-48.
3. Chin KJ, Kempin S, Milman T, Finger PT. Ocular Manifestations of Multiple Myeloma: Three cases and a review of the literature. *Optometry*. 2011;82(4): 224-230.
4. Altekruse SF, Kosary CL, Krapcho M, et al (eds). SEER Cancer Statistics Review, 1975-2007, National Cancer Institute. Bethesda, MD. Available at: http://seer.cancer.gov/csr/1975_2007/, based on November 2009 SEER data submission, posted to the SEER Web site, 2010. Accessed August 21, 2017.
5. Dahlman G. Multiple Myeloma. *A Science Writer's Guide to Multiple Myeloma*. 2003: 1-8.
6. Omoti AE, Omoti CE. Ophthalmic Manifestation of Multiple Myeloma. *West African Journal of Medicine*. 2007;26(4): 265-268.
7. Orellana J, Friedman AH: Ocular manifestations of multiple myeloma, Waldenström's macroglobulinemia and benign monoclonal gammopathy. *Surv Ophthalmol* 1981;26:157–169.
8. Knapp AJ, Gartner S, Henkind P: Multiple myeloma and its ocular manifestations. *Surv Ophthalmol* 1987;31:343–351.
9. Dogan B, Erol MK, Toslak D, Coban DT, Bulut M, Cengiz A, Sari ES. Serous Macular detachment, yellow macular deposits, and prominent middle limiting membrane in multiple myeloma. *Therapeutics and Clinical Risk Management*. 2015;11: 683-689.
10. Mehta J, Singhal S. Hyperviscosity syndrome in plasma cell dyscrasias. *Semin Thromb Hemost*. 2003;29:467–471.
11. Brody JM, Butrus SI, Ashraf F, Rabinowitz AI, Whitmore PV. Multiple myeloma presenting with bilateral exudative macular detachments. *Acta ophthalmologica Scandinavica*. 1995: 73:81-82
12. Granis CH, Dewan VN, Wang RC. Resolution of Bilateral Cystoid Macular Edema and Subfoveal Serous Retinal Detachments after Treatment with Bortezomib in Patient with Smoldering Multiple Myeloma. *Retinal Cases and Brief Reports*. 2014: 8: 348-351.
13. Sharma A, Lokheswar N, Raina V, Mohanti BK, Kumar R. Melphalan and dexamethasone for patients with multiple myeloma who are not candidates for autologous stem cell transplantation. *The National Medical Journal of India*. 2007: 20(3): 121-124.
14. Kyle RA, Rajkumar V. Criteria for Diagnosis, Staging, risk stratification and response assessment of Multiple Myeloma. *Leukemia*. 2009: 23(1): 3-9.
15. Eby C. Pathogenesis and management of bleeding and thrombosis in plasma cell dyscrasias. *British Journal of HHaematology*. 2009: 145:151-163.



This work licensed under Creative Commons Attribution